

*Sirimontaporn N, M.D.*

*Rerknimitr R, M.D.*

### Case 1

36-year-old Thai male presented with dyspeptic symptom, poor appetite, skin lesion and weight loss. EGD and colonoscopy were performed with finding submucosal mass 1 cm. in diameter at lesser curvature of stomach with hyperpigmented central umbilication (as shown in the following figures)

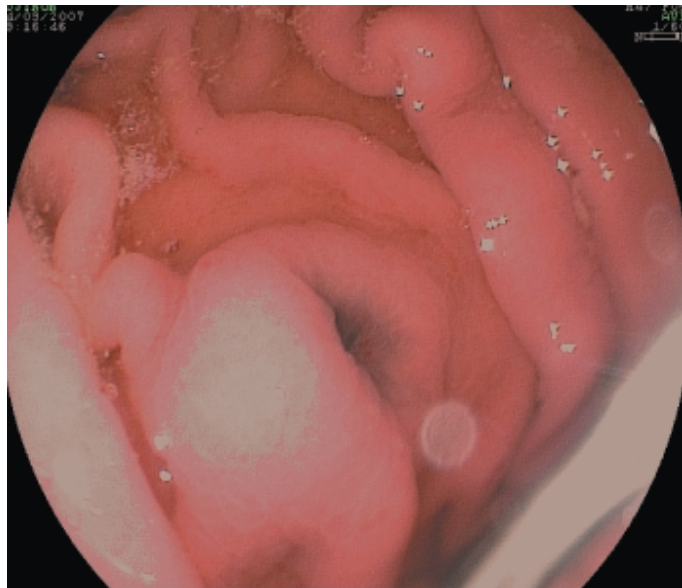


Figure 1

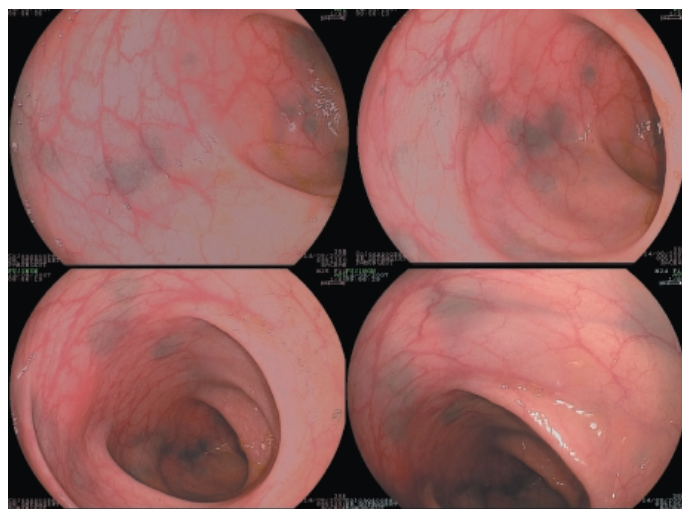


Figure 2

Sirimontaporn N, Rerknimitr R

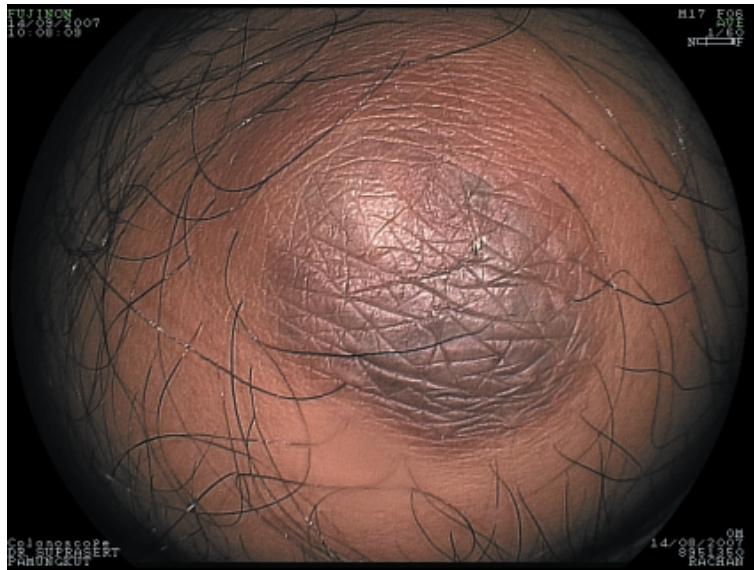

Figure 3

What is the most likely diagnosis? (Answer see page 138)

**Case 2:**

5-year-old Thai male had the history of 1-year chronic diarrhea and HIV seropositive. He has regularly taken steroid tablet twice daily. The colonoscopy was performed and found erythematous mucosal swelling with multiple ulcers varying in size with skip area from sigmoid colon up to cecum.

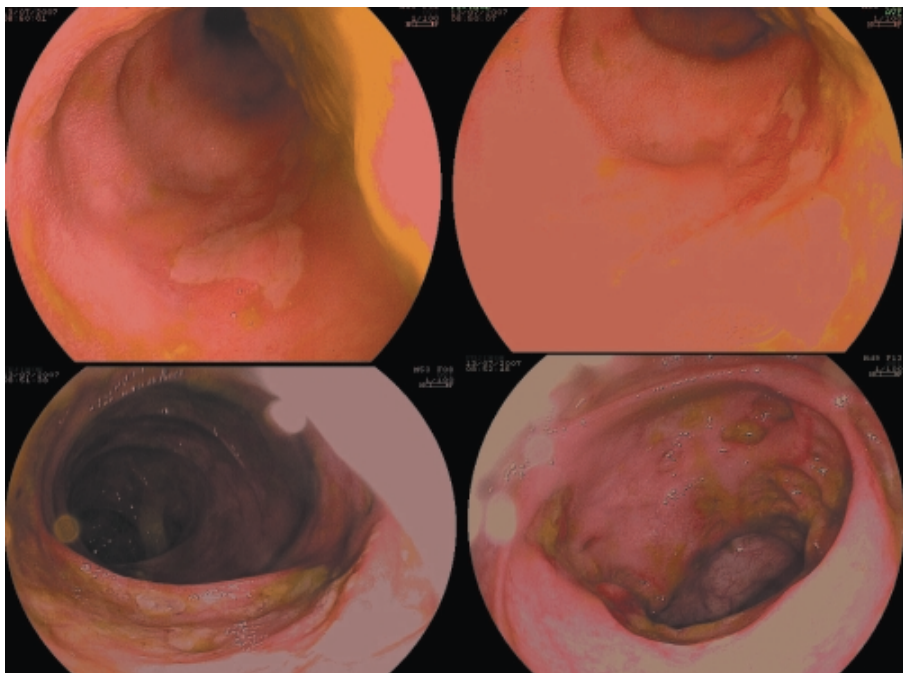


Figure 4

What is the diagnosis? (Answer see page 138)

**Case 3:**

45-year-old Thai male presented to the hospital with dyspepsia for 6 months which did not response to antacid. EGD was revealed the umbilicated submucosal lesion in antrum.

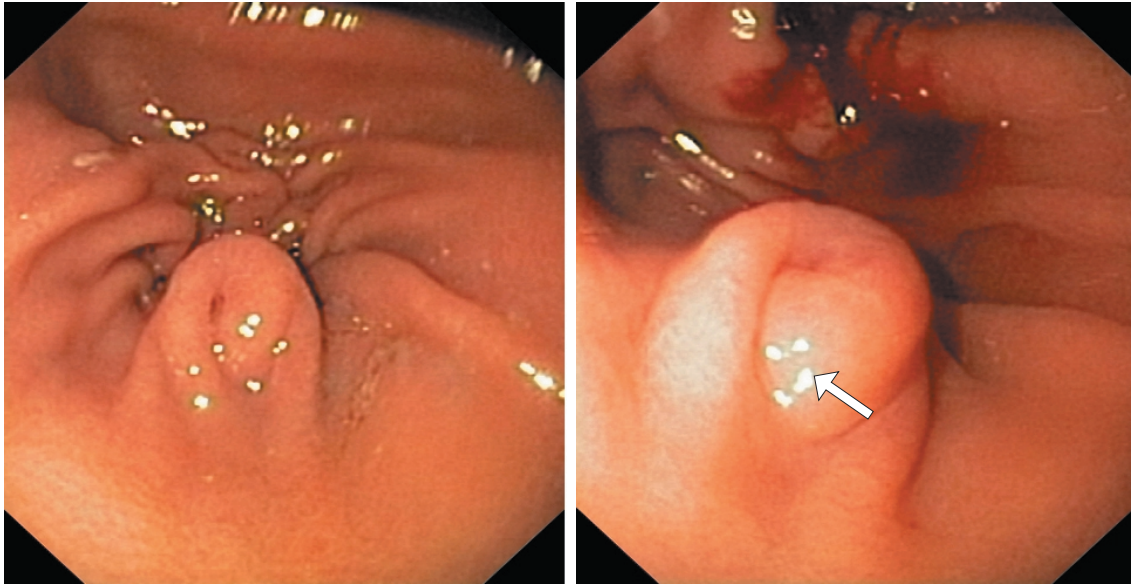


Figure 5

What is the most likely diagnosis? (Answer see page 138)

**Answer for endoscopic quiz:**

Case 1 = **Malignant Melanoma**

Case 2 = **CMV Colitis**

Case 3 = **Ectopic Pancreas (Pancreas Heterotopia)**