

A Thai Woman with Dyspnea after Glue Injection for Gastric Variceal Bleeding

Danai Limmathurotsakul, M.D.
Rungsun Rerknimitr, M.D.

ABSTRACT

Bleeding gastric varices are increasingly being treated with endoscopic injection of N-butyl-2-cyanoacrylate (histoacryl) diluted with lipiodol. Severe glue induced pulmonary embolism is a rare complication of injection therapy. We reported a 72 years old Thai woman who first presented with gastric variceal bleeding. After therapeutic endoscopy with cyanoacrylate injection, she developed dyspnea and hypoxia. Her chest radiography revealed multiple glue emboli in both lungs. After supportive treatment with oxygen therapy, she gradually improved to normal respiratory condition.

[Thai J Gastroenterol 2006; 7(3): 171-174]

Case report

A 72 year-old Thai woman came to the hospital with hematemesis. She also complained of epigastric discomfort for 3 days. She had dark bloody content on vomiting twice a day for 2 days. She had been diagnosed as autoimmune hepatitis with child class A cirrhosis for 4 years. She had previous upper GI bleeding 4 years ago.

Physical examinations revealed stable vital signs. She had no jaundice. The liver span was normal with no other stigmata of chronic liver disease. Mild tenderness at left lower quadrant of abdomen was detected. The spleen was not palpated.

Hemoglobin on admission was 8.8 gm/dl (nor-

mal 12.5-15.5 g/dl.). White blood count was 15,700/ml with 88% of neutrophil. Platelet count was 100,000/mm³. Prothrombin time was 16.5 (control 12.6) with INR of 1.3. Other blood tests were unremarkable. Chest radiography (Figure 1) was unremarkable.

Hospital course

Esophagogastroduodenoscopy (EGD) was performed immediately. It revealed no esophageal varices but a large isolated gastric varice (IGV) with small ulcer and pigmented spot. There also were multiple duodenal ulcers size 0.3-1.5 cm and one with non-bleeding visible vessel (NBVV) at the junction between duodenal bulb and the 2nd part of duodenum.

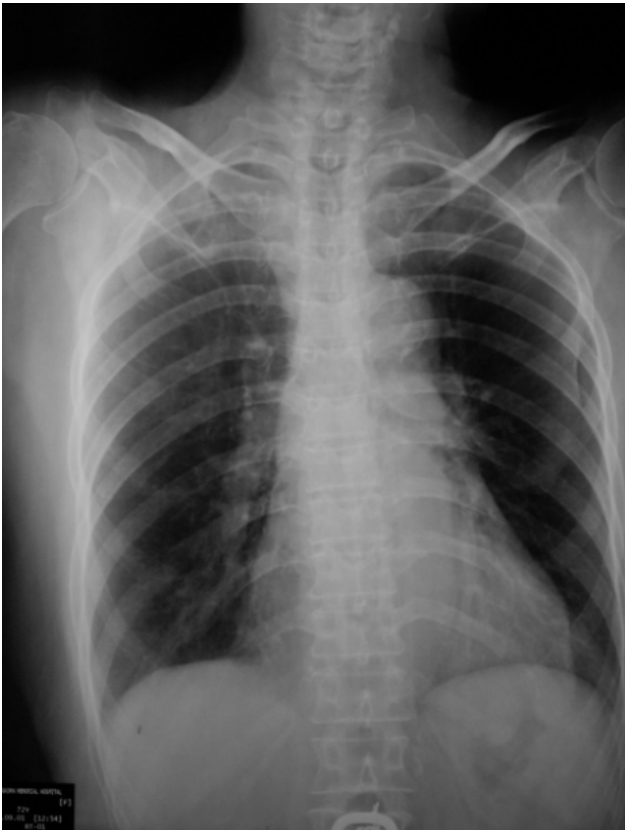


Figure 1 Chest radiography before glue injection

Bipolar coaptation was applied and successfully controlled NBVV. The 3 doses combination of histoacryl (0.5 ml) and lipiodal (0.8 ml) were injected into IGV with no immediate complication. Intravenous pantoprazole and sandostatin were also given.

After she went back to the ward, she developed acute tachypnea not related to the position. She had no orthopnea or paroxysmal nocturnal dyspnea. She reported no chest discomfort or hemoptysis. Her physical examination revealed no abnormalities. Her oxygen saturation on room air was 88%. Arterial blood gas at room air showed pH: 7.439, pO_2 : 43, pCO_2 : 25.7, HCO_3^- : 17, O_2 sat: 81.6 and A-a gradient 74.6 Her chest film (Figure 2) revealed generalized small opacities distributed along pulmonary vasculature in both sides of lung parenchyma with enlarged cardiac size and pulmonary trunks. The diagnosis of glue induced pulmonary emboli was entertained. Oxygen therapy via nasal canula was given and her oxygen saturation increased up to 95%.

Day 2 in the hospital her hematocrit decreased from 33% to 25%. Repeat EGD was performed. It revealed IGV with red color sign and minimal blood

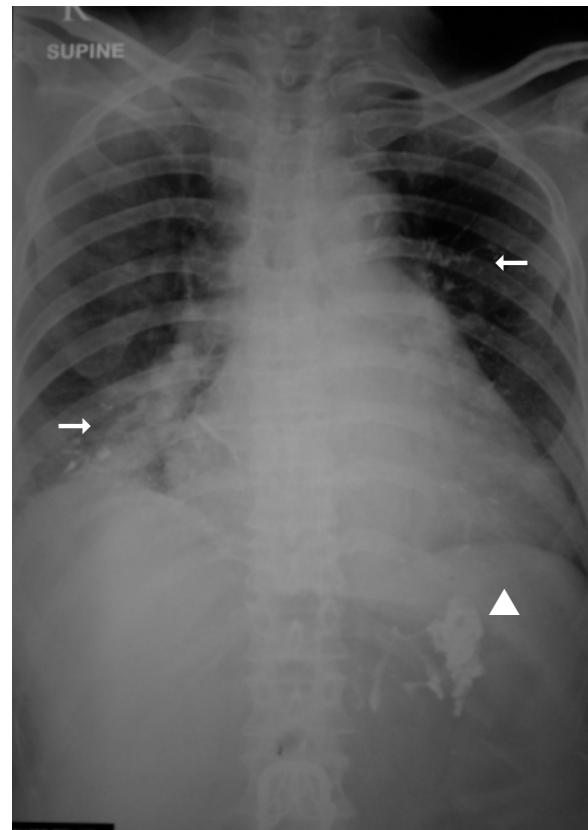


Figure 2 Chest radiograph after glue injection showed enlarged cardiac size and pulmonary trunks with small opacities in both lungs (arrow). The opacities from the site of injection were detected in the area of gastric varices (arrowhead).

content in the gastric antrum. Histoacryl 0.5 ml and lipiodal 0.8 ml was injected in the same varix. She had no immediate complication and bleeding was stopped. At this time, there was no pulmonary complication and her oxygenation was stable. She had been admitted in the hospital for 6 days. She went back home with home oxygen therapy for 2 weeks. When she presented back for a follow up, she reported no dyspnea and her oxygen saturation on room air was stable at 95%.

DISCUSSION

We presented a 72 years old woman with child class A cirrhosis who developed dyspnea and hypoxia after therapeutic esophagogastroduodenoscopy for gastric variceal bleeding with N-butyl-2-cyanoacrylate injection.

The most common causes of hypoxia in the cirrhotic patient are hepatopulmonary syndrome which

usually shows orthodeoxia and N-butyl-2-cyanoacrylate injection induced pulmonary emboli.

N-butyl-2-cyanoacrylate is a tissue adhesive that increasingly being used to control bleeding gastric varices.⁽¹⁾ The efficacy is similar to variceal ligation but glue injection is associated with a lower rebleeding rate.⁽²⁾ This glue acts as a tissue adhesive that immediately polymerizes on contact with weak bases such as blood. This carries the risk for gluing the injector needle to the varix. The attempted removal of such a needle can cause fatal bleeding. Hence, 1 ml of cyanoacrylate diluted with 1-3 ml of lipiodal to prevent premature polymerization is recommended. However, this can still cause other complications especially distal embolization.

Blood supply to the fundal GV is originate from short gastric and epiploic veins, which drain to the left renal vein via large gastrosplenic shunt⁽³⁾ and then to IVC and right sided heart. (Figure 3) Then embolization can occur in any organ via this shunt. Lungs are the most common site of embolization⁽⁴⁾.

From previous report, Hwang, *et al.*⁽⁵⁾ found pulmonary emboli in 6 (4.3%) of 140 patients received glue injection. Mean volume of injection in this study in PE group were 4.16 ± 1.03 ml was significant different from non PE group that were 1.76 ± 0.58 ml ($p = 0.0011$)

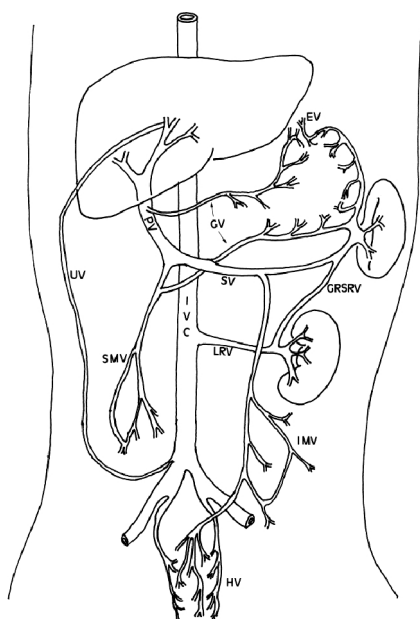


Figure 3 Common collateral venous system in portal hypertension

Risk factors for glue pulmonary emboli included more than 1 ml injection with excess lipiodal (cyanoacrylate/lipiodal ratio below 5:8 v/v), injection of excess distilled water with the needle still in the varix, slow injection, and high flow rate of the large varix.⁽⁶⁾

Diagnosis usually confirmed by history, physical examination and basic investigation. Using CT angiography to diagnose glue induce pulmonary emboli is difficult due to emboli can be masked by intravenous contrast material.⁽⁷⁾

Glue emboli usually require only symptomatic treatment. Majority of the patients had a complete response. Hwang, *et al.* reported 4 of 6 patients were completely resolved from respiratory deconditioning, 1 patient was partially resolved and another had low grade sequel.⁽⁵⁾ There is one study showed the benefit of oral prednisone but no dosage was detailed.⁽¹⁾

Due to glue emboli can occur in any organ. There were reports of mesenteric emboli⁽⁸⁾, cortical blindness, inferior wall myocardial infarction in patients with patent foramen ovale⁽⁹⁾ and septic emboli.^(10,11)

In our previous report, Noophun *et al.*⁽⁸⁾ reported one case of pulmonary emboli and one case of mesenteric emboli from 24 GV patients who underwent glue injections. The patient with pulmonary emboli had a completely recovery similar to this case. But the patient with mesenteric emboli developed severe peritonitis and finally expired.

In conclusion, glue induced pulmonary emboli is a rare complication associated with injection therapy for GV bleeding. Most emboli associated with a large volume of glue injection and poor technique of injection. Awareness of this complication is essential. However prevention by reducing the risk factor for embolization is more important but very difficult.

REFERENCES

- Alexander S, Korman MG, Sievert W. Cyanoacrylate in the treatment of gastric varices complicated by multiple pulmonary emboli. *Int Med J* 2006; 36: 462-5.
- Tan P, Hou M, Lin H, *et al.* A randomized trial of endoscopic treatment of acute gastric variceal hemorrhage: N-butyl-2-cyanoacrylate injection versus band ligation. *Hepatology* 2006; 43: 690-7.
- Watanabe K, Kimura K, Matsutani S, *et al.* Portal hemodynamics in patients with gastric varices: a study in 230 patients with oesophageal and/or gastric varices using portal vein catheterization. *Gastroenterology* 1988; 95: 434-40.

4. Imazu H, Matsu T, Kobayasi Y, *et al.* Balloon catheter-assisted endoscopic sclerotherapy for gastric fundal varices using alpha-cyanoacrylate monomer. *J Clin Gastroenterol* 2001; 33: 49-52.
5. Hwang S, Kim H, Park S, *et al.* N-butyl-2-cyanoacrylate pulmonary embolism after endoscopic injection sclerotherapy for gastric variceal bleeding. *J Comput Assist Tomogr* 2001; 25: 16-22.
6. Van Beek A, Van Erpecum K. Fatal N-Butyl-2-Cyanoacrylate pulmonary embolism after sclerotherapy for variceal bleeding. *Endoscopy* 2005; 37: 687.
7. Rickman O, James P, Gregory L, *et al.* Pulmonary embolization of 2-octyl cyanoacrylate after endoscopic injection therapy for gastric variceal bleeding. *Mayo Clin Proc* 2004;79: 1455-8.
8. Noophun P, Komkham P, Gonlacharnvit S, *et al.* Bleeding gastric varices: results of endoscopic injection with cyanoacrylate at King Chulalongkorn Memorial hospital. *World J Gastroenterol* 2005; 11: 7531-5.
9. Upadhyay AP, Ananthasivan R, Radhakrishnan S, *et al.* Cortical blindness and acute myocardial infarction following injection of bleeding gastric varices with cyanoacrylate glue. *Endoscopy* 2005; 37: 1034.
10. Turler A, Wolff M, Dorlars D, *et al.* Embolic and septic complications after sclerotherapy of fundic varices with cyanoacrylate. *Gastrointest Endosc* 2001; 53: 228-30.
11. Tan Y, Goh K, Kamarulzaman A, *et al.* Multiple systemic embolisms with septicemia after gastric variceal obliteration with cyanoacrylate. *Gastrointest Endosc* 2002; 55: 276-8.