

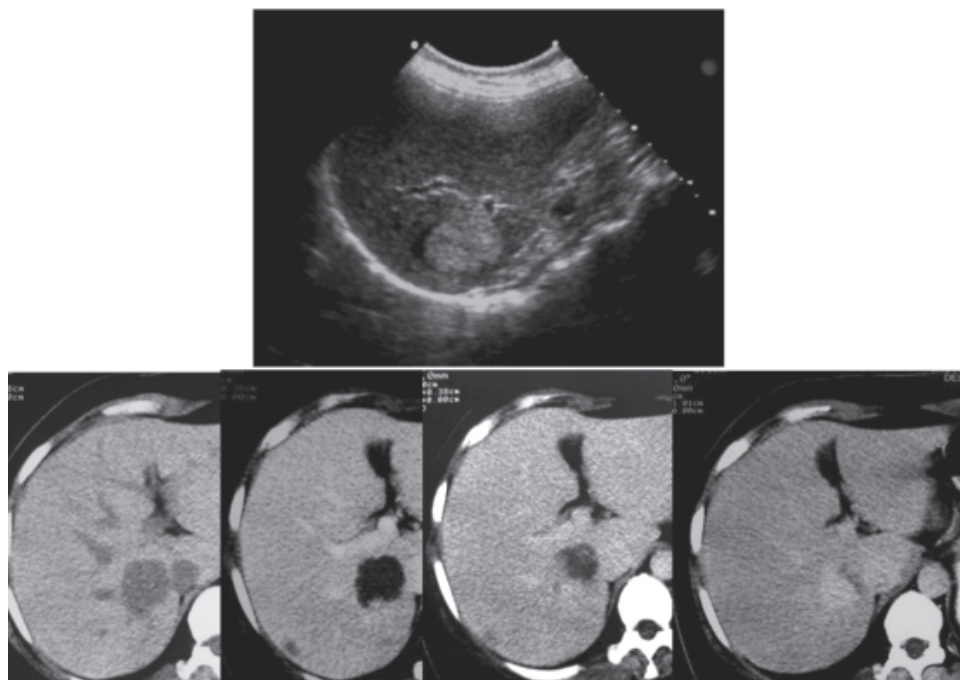
## Imaging of The Liver

*Pantongrag-Brown L.*

Imaging modalities used in liver include ultrasound (US), CT, and MRI. US is usually the first imaging modality performed when liver abnormality is suspected. This is because US is relatively cheap, accessible, and easy to perform. Although US is sensitive for detection of liver nodules or masses, it is not specific or accurate for making definitive diagnosis. CT or MRI are usually needed to further characterize the lesions. Both CT and MRI are very good to delineate the nature of the lesions, but MRI has better advantage in soft-tissue characterization without exposure to radiation.

In this article, several liver abnormalities will be demonstrated, using case-based approach, and emphasizing on imaging findings.

**Case 1.** A 35-year-old woman coming for US check-up.

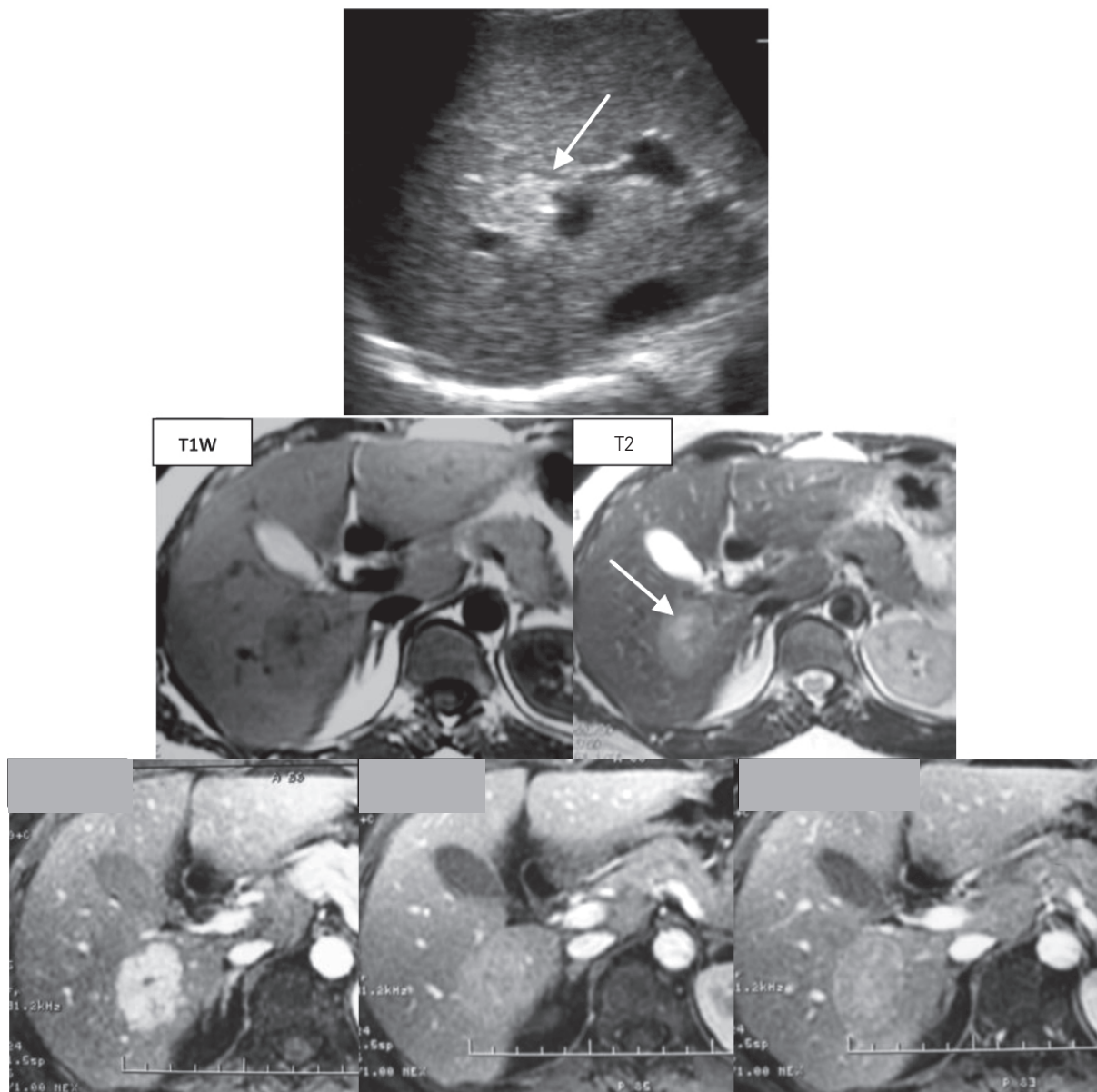


**Figure 1.** Case 1.

US shows a 3.0 cm well-defined, hyper-echoic nodule of the right hepatic lobe. Finding is not specific for any particular pathology, but probably benign because of the nature of incidental finding. Contrast enhanced CT is performed to further characterize the lesion. The mass shows peripheral nodular enhancement, central filling-in, and persistent enhancement throughout delayed phase. Findings are characteristic for a benign hemangioma.

Hemangioma is the most common benign liver tumor, accounting for about 1-2% in the general population<sup>(1)</sup>. It is composed of multiple vascular channels lining by endothelial cells. Typical findings of hemangioma include hyper-echoic nodule at US, very high signal intensity at T2W MRI, and peripheral nodular enhancement with delayed central filling-in at CT or MRI<sup>(2)</sup>. However, atypical appearance of hemangioma is not uncommon, and found in approximately 20-40% of cases<sup>(1)</sup>. If typical by CT or MRI, follow-up of hemangioma is varied among various institutions, from no follow-up to 6-12 months follow-up to confirm stability<sup>(3)</sup>.

**Case 2.** A 37-year-old woman coming for US check-up.

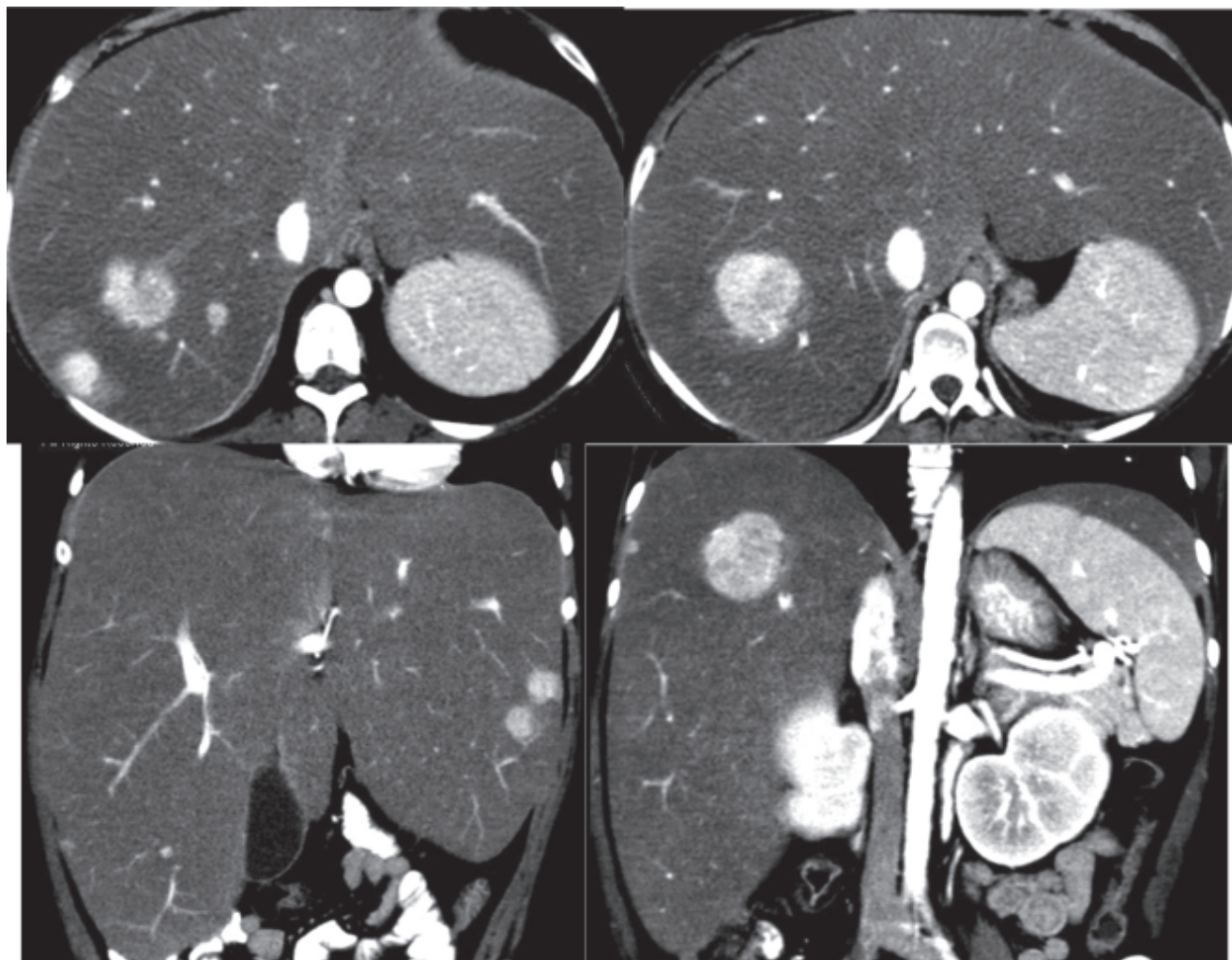


**Figure 2.** Case 2.

US shows a 2.0 cm ill-defined, slightly hyper-echoic nodule of the right hepatic lobe (arrow). Finding is not specific for any particular pathology, but probably benign because of the nature of incidental finding. MRI shows a lobulated nodule with small central scar. The small scar appears high SI at T2 (arrow). The mass shows homogeneous enhancement at arterial phase, slightly high signal to the liver at venous phase, and enhancement of central scar at delayed phase. Findings are characteristic for a benign focal nodular hyperplasia (FNH).

FNH is the second most common benign liver tumor. Although exogenous estrogens does not cause FNH, it may stimulate the growth of the mass<sup>(4)</sup>. It is believed to be hyperplastic response of hepatocytes to vascular malformations<sup>(4,5)</sup>. FNH could be multiple in about 20% of cases, and could be found with hemangioma in about 23%<sup>(4)</sup>. FNH and hepatic adenoma may show similar appearance on US, CT, and conventional MRI. Differentiation is important because risk of malignant change and complication may occur in hepatic adenoma. MRI with hepatobiliary specific contrast agent could distinguish FNH from hepatic adenoma. FNH usually shows uptake of this contrast agent, whereas adenoma does not. FNH is a benign lesion and, if diagnosed, should be treated conservatively<sup>(5)</sup>.

**Case 3.** A 28-year-old woman, underlying glycogen storage disease, presenting with abdominal pain.



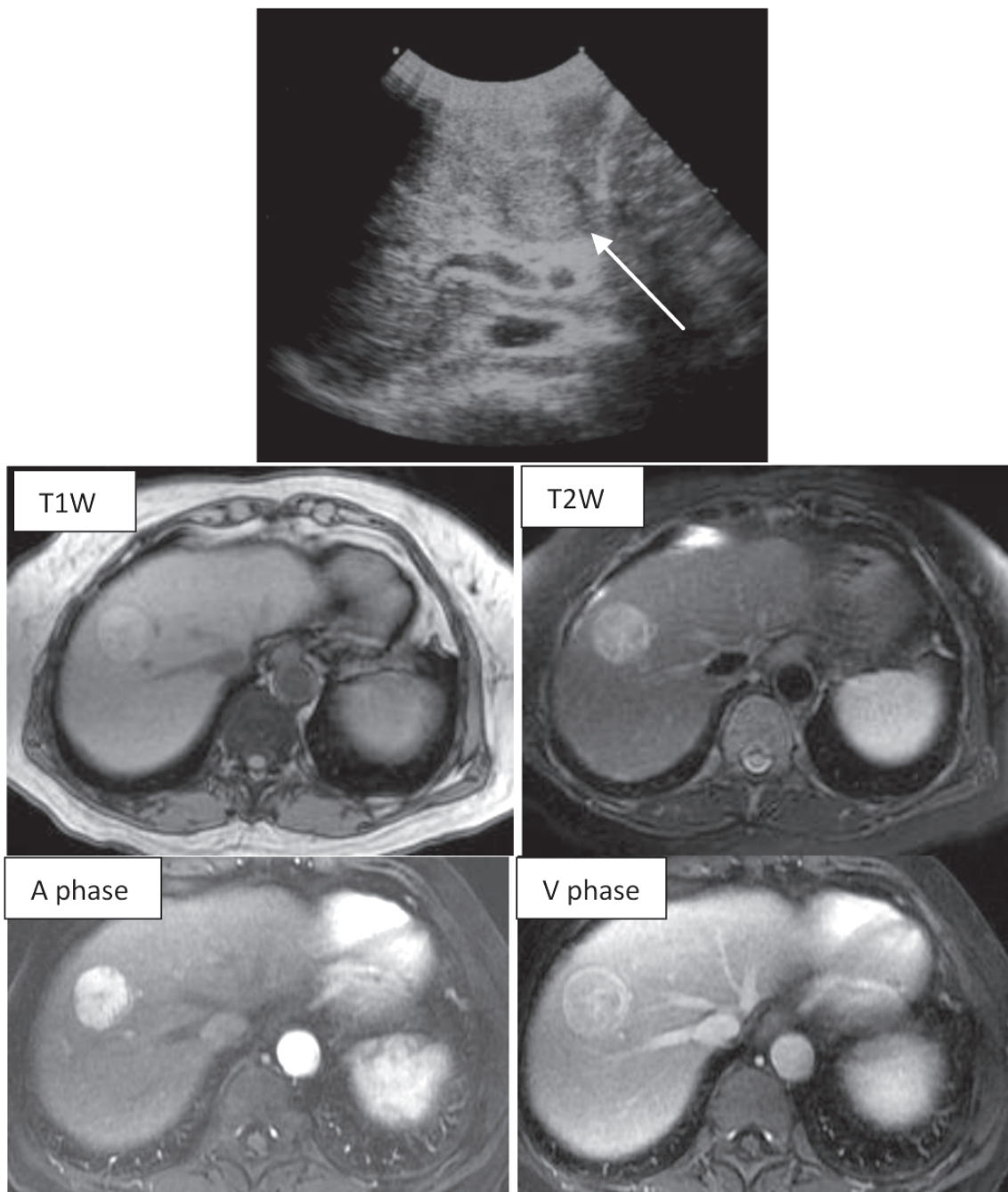
**Figure 3.** case 3.

CT with IV contrast shows multiple hypervascular nodules scattering within the liver. The background liver shows hepatomegaly with diffuse fatty change. Differential diagnosis (D/Dx) of multiple hypervascular nodules includes FNHs, hepatic adenomas, HCCs, and metastasis. Hepatomegaly and severe fatty liver are consistent with underlying glycogen storage disease. Given such underlying disease, these nodules are consistent with hepatic adenomatosis.

Hepatic adenoma is usually occur in a young female with history of oral contraceptive pills. There are 3 types of hepatic adenomas; inflammatory hepatic adenomas, HNF1 alpha-mutated hepatic adenomas, and beta catenin-mutated hepatic adenomas<sup>(6)</sup>. These 3 subtypes of hepatic adenomas have different prognosis and management strategies<sup>(7)</sup>. Multiple hepatic adenomas or hepatic adenomatosis are frequently observed in type I glycogen storage disease (von Gierke's disease), and usually are beta catenin-mutated type with high risk of developing into hepatocellular carcinoma.

Hepatic adenomas have a tendency to hemorrhage and certain type of hepatic adenomas may develop into hepatocellular carcinomas. If diagnosed, a large hepatic adenoma over 5 cm should be surgically removed, and a small one should be under surveillance until menopause<sup>(8)</sup>.

**Case 4.** A 45-year-old man with chronic HBV, showing a liver nodule during US surveillance.

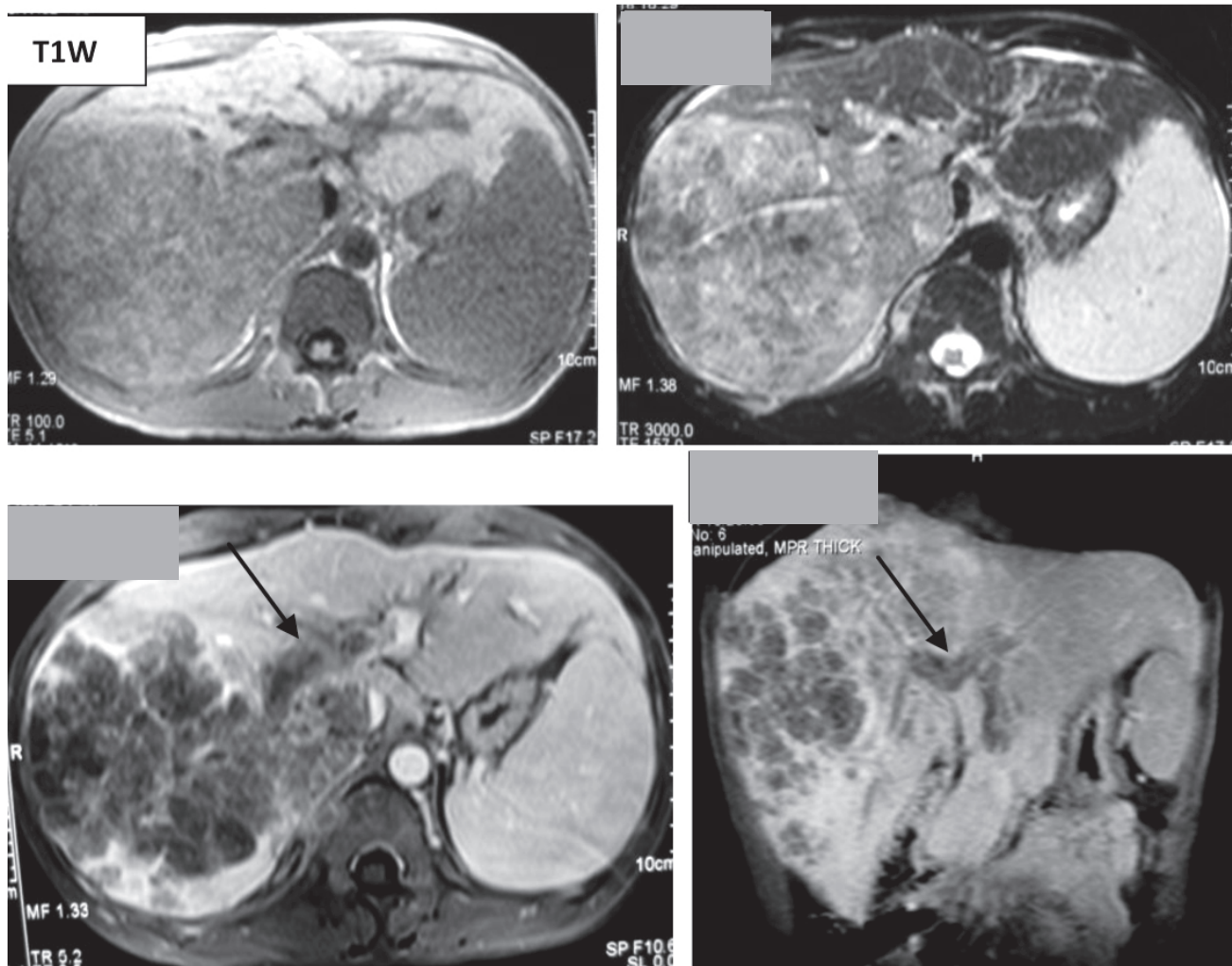


**Figure 4.** case 4.

US shows a 3.0 cm hyper-echoic nodule with a thin hypo-echoic rim (arrow). D/Dx based on US includes regenerating nodule, dysplastic nodule, and HCC. MRI reveals an encapsulated nodule showing arterial enhancement, and venous washout, which is characteristic for a small HCC.

US is sensitive for detecting liver nodule, and recommended for surveillance of HCC in chronic liver disease<sup>(9)</sup>. Patients should be screened for 6 months interval, and the surveillance interval does not need to be shortened for patients at higher risk for HCC<sup>(10)</sup>. Although sensitive, US is not specific to accurately diagnose HCC, and further investigation by contrast enhanced CT or MRI is needed<sup>(11)</sup>. Characteristic findings of HCC in both CT and MRI include rapid arterial enhancement and venous or delayed washout, as shown in this case.

**Case 5.** A 32-year-old male presenting with palpable abdominal mass.

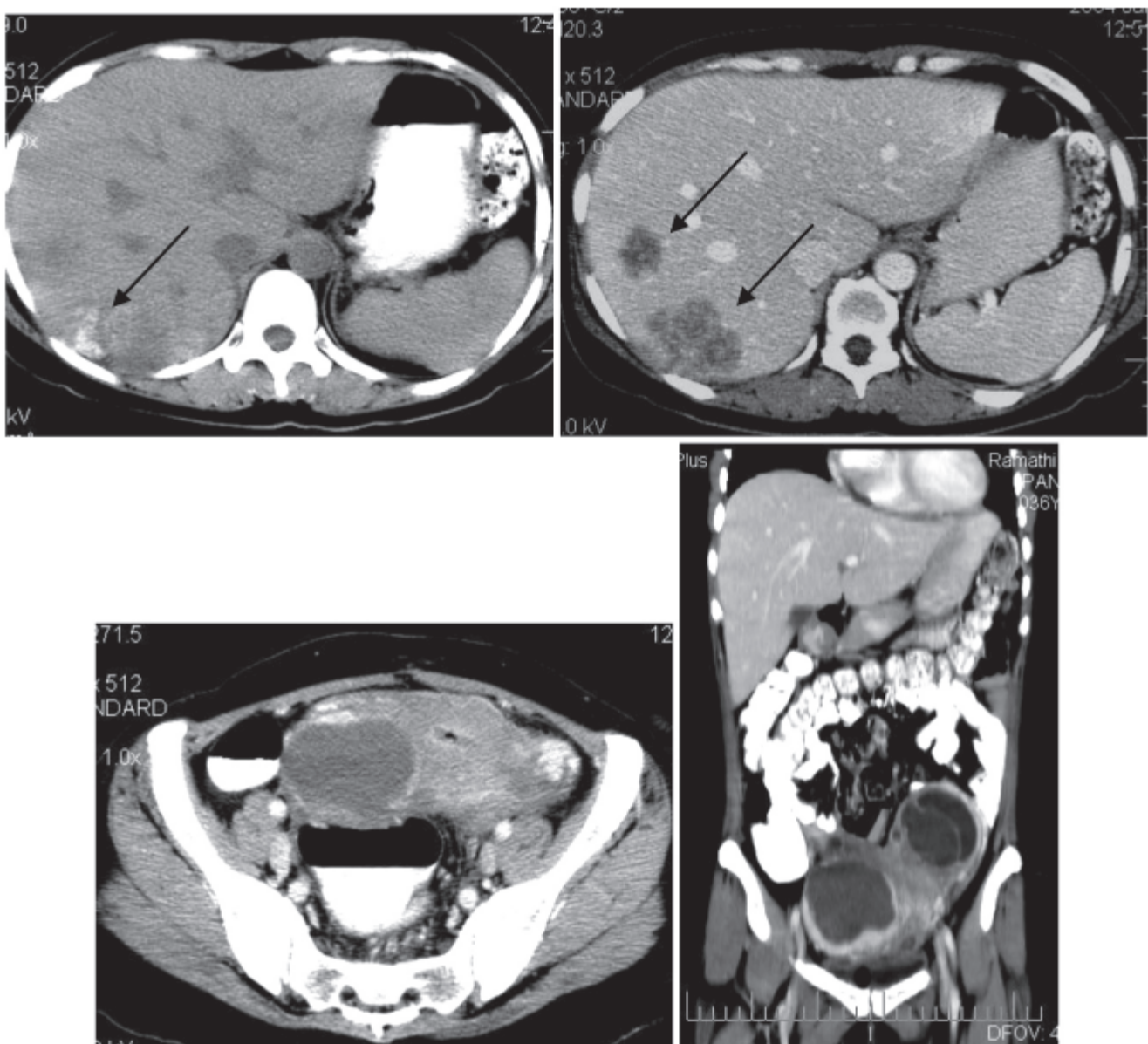


**Figure 5.** case 5.

MRI shows a huge mass within right hepatic lobe with evidence of invasion of the right portal vein (PV), left PV, and main PV (arrows). Findings are suggestive of malignant liver tumor. D/Dx includes HCC, fibrolamellar carcinoma, cholangiocarcinoma, and unusual sarcoma. Enlarged left hepatic lobe and splenomegaly are indicative of chronic liver parenchymal disease. Given the underlying chronic liver disease and evidence of PV invasion, the most likely diagnosis is a large HCC. Biopsy confirms the diagnosis of HCC.

HCC is the most common primary malignant tumor of the liver. It is the 5<sup>th</sup> most common cancer in the world, and the 3<sup>rd</sup> most common cause of cancer-related death<sup>(12)</sup>. Common risk factors are chronic hepatitis B, chronic hepatitis C, and alcoholic cirrhosis. HCC can have multiple appearances, such as a large mass, a small nodule, or an infiltrative pattern. HCC has a tendency to invade vascular structures, particularly portal vein, but hepatic veins and IVC may also be involved.

**Case 6.** A 36-year-old female presenting with abdominal discomfort.



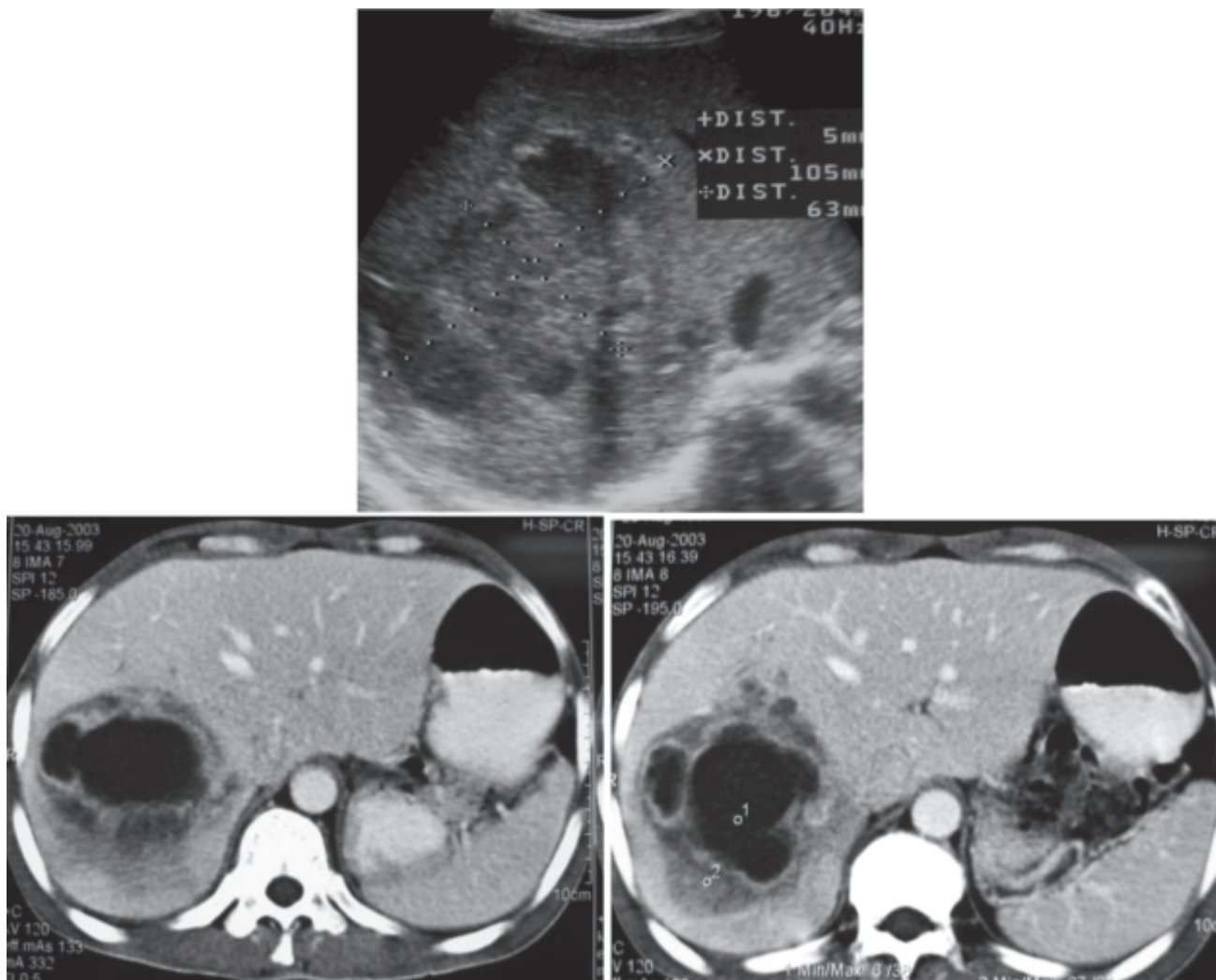
**Figure 6.** case 6.

CT shows low-density liver nodules at the right lobe, containing calcification (arrows). D/Dx of calcified liver nodules includes granulomatous disease (such as TB), cholangiocarcinoma, and metastasis. CT images at the pelvis shows a large, mixed solid-cystic mass, suggestive of ovarian cancer. Given, the finding of the ovarian mass, the liver nodules are most likely metastases. Surgery confirms diagnosis of CA ovary with liver metastasis.

Hepatic metastases are more common than primary liver neoplasms<sup>(13)</sup>. GI tract and GU tract are the 2 most common primary sites to metastasize to the liver. Calcified liver metastases are uncommon, and primary tumor may originate from GI tract, ovary, breast, pancreas, or osteosarcoma. Most liver metastases are multiple, although solitary metastasis is not uncommon.

Pantongrag-Brown L

**Case 7.** A 48-year-old man presenting with abdominal pain and fever.



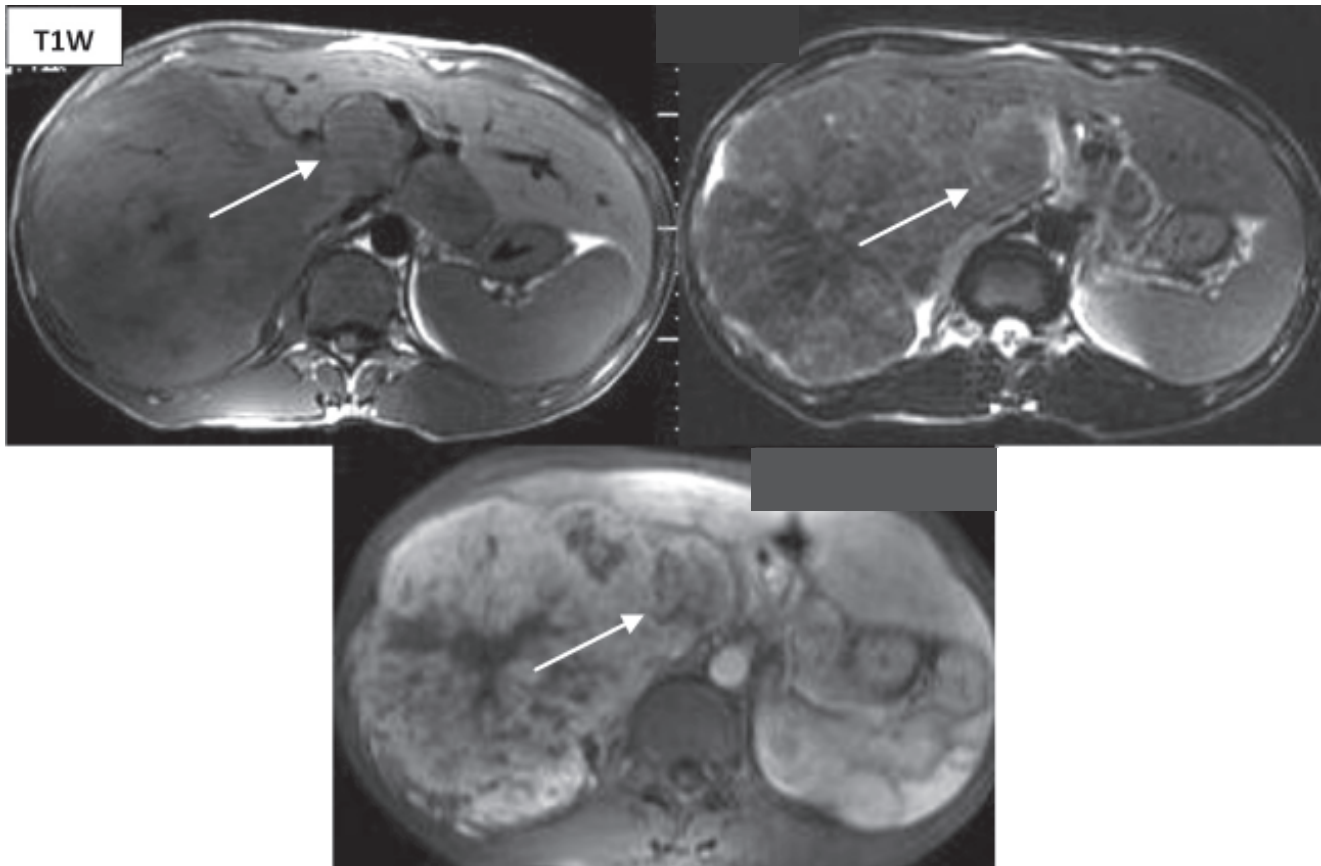
**Figure 7.** case 7.

US shows a complex mass at right hepatic lobe, which may represent either abscess or necrotic tumor. CT shows the mass to be cystic with thin rim enhancement and perilesional edema. Findings are favorable for liver abscess. Aspiration of the cystic content confirms that the lesion is a pyogenic abscess.

Liver abscess and necrotic tumor may be difficult to distinguish. Both clinical and imaging findings are required to make the correct diagnosis. RUQ pain and fever is a classic clinical presentation of liver abscess. Thin rim enhancement of a cystic mass with perilesional edema and hyperemia are indicative of liver abscess. Cystic tumor usually shows nodular, irregular rim enhancement. Eventually, tissue biopsy or aspiration is needed to confirm the diagnosis.

Liver abscess may be caused by bacterial, parasitic, or fungal agents<sup>(14)</sup>. Parasitic liver abscess is usually found in developing countries. In developed countries, liver abscess is usually pyogenic secondary to underlying GI tract diseases, such as diverticulitis, appendicitis, or hidden colon cancer.

**Case 8.** A 35-year-old man presenting with palpable abdominal mass without underlying liver disease.



**Figure 8.** case 8.

MRI shows a large hypervascular mass with central scar and invasion of the IVC (arrows). Findings are indicative of malignant liver tumor. D/Dx includes HCC, fibrolamellar carcinoma (FLC), and cholangiocarcinoma. Biopsy proves this mass to be a FLC.

FLC is a rare primary liver tumor. It has a unique feature that is different from HCC. FLC usually occur in young individual without sex predilection. Patient does not have underlying liver disease nor elevation of alpha-fetoprotein. A large central scar mass in a young person without underlying chronic hepatitis or cirrhosis is a clue to diagnose FLC. FLC has better prognosis than HCC, and surgical resection is the treatment of choice<sup>(15)</sup>.

## CONCLUSIONS

Eight cases of liver diseases are illustrated, emphasizing on the imaging appearances. These cases are as following:

1. Benign neoplastic pathology:
  - a. Hemangioma
  - b. FNH
  - c. Hepatic adenomatosis
2. Malignant neoplastic pathology:
  - a. Small HCC
  - b. Large HCC

- c. Hepatic metastasis
3. Infectious/inflammatory pathology:
  - a. Liver abscess

## REFERENCES

1. Moody AR, Wilson SR. Atypical hepatic hemangioma: a suggestive sonographic morphology. *Radiology* 1993;188:413-7.
2. Pantongrag-Brown. Multiple faces of liver hemangiomas. *Thai J Gastroenterol* 2007;8:91-8.



3. Leifer DM, Middleton WD, Teefey SA, *et al.* Follow-up of patients at low risk for hepatic malignancy with a characteristic hemangioma at US. *Radiology* 2000;214:167-72.
4. Lencioni R, Cioni D, Bartolozzi C. Focal liver lesions, detection, characterization, ablation. Springer Verlag; 2005. ISBN: 3540644644.
5. Grazioli L, Morana G, Kirchin MA, *et al.* Accurate differentiation of focal nodular hyperplasia from hepatic adenoma at gadobenate dimeglumine-enhanced MR imaging: prospective study. *Radiology* 2005;236:166-77.
6. Bioulac-Sage P, Laumonier H, Couchy G, *et al.* Hepatocellular adenoma management and phenotypic classification: the Bordeaux experience. *Hepatology* 2009;50:481-9.
7. Pantongrag-Brown L. Current concept of hepatic adenomas: MRI and genetic correlation. *Thai J Gastroenterol* 2012;13:134-7.
8. Kathabathina VS, Menias CO, Shanbhogue AKP, *et al.* Genetics and imaging of hepatocellular adenomas: 2011 update. *RadioGraphics* 2011;31:1529-43.
9. Bruix J, Sherman M. Management of hepatocellular carcinoma: an update. *Hepatology* 2011;53:1020-2.
10. Zhang BH, Yang BH, Tang ZY. Randomized controlled trial of screening for hepatocellular carcinoma. *J Cancer Res Clin Oncol* 2004;130:417-22.
11. Pantongrag-Brown L. Role of imaging in hepatocellular carcinoma. *Thai J Gastroenterol* 2014;15:56-60.
12. Parkin DM, Bray F, Ferlay J, *et al.* Estimating the world cancer burden: Globocan 2000. *Int J Cancer* 2001;94:153-6.
13. Namasivayam S, Martin DR, Saini S. Imaging of liver metastases: MRI. *Cancer Imaging* 2007;7:2-9.
14. Krige JEJ, Beckingham IJ. ABC of diseases of liver, pancreas, and biliary system: Liver abscesses and hydatid disease. *BMJ* 2001;322:537-40.
15. Dhakshinamoorthy G, Janio S, Vikas K, *et al.* Imaging features of fibrolamellar hepatocellular carcinoma. *AJR* 2014;202:544-52.