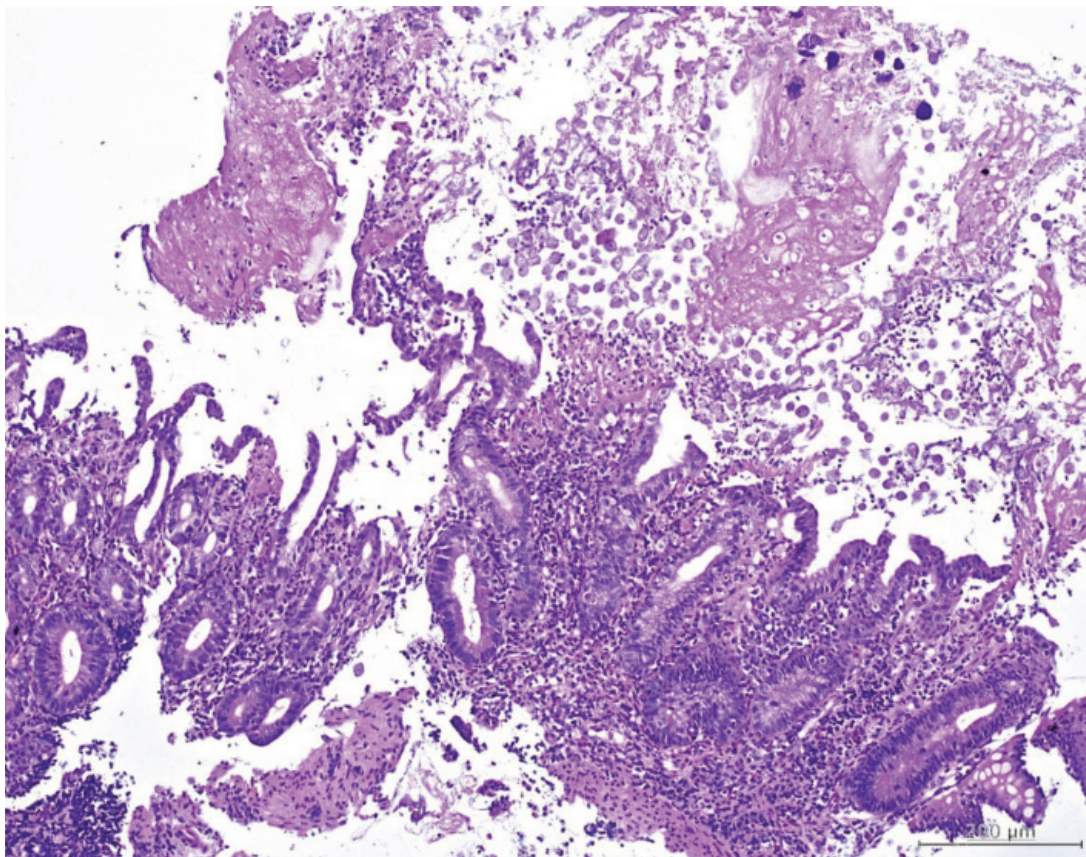


*Klaikeaw N***Case 1**

A 19-year-old male presented with lower abdominal cramps, fever and mucous bloody diarrhea about four weeks. On endoscopic examination, small mucosal ulcers covered with yellowish exudates are observed. The mucosal lining between the ulcers appears normal. Biopsy results colitis with erosion and increased eosinophilic infiltration. There are clumps of large round organisms in fibrinonecrotic tissue overlying the mucosa, morphologically consistent with trophozoites of *Amoeba* (Figure 1-2).

**Figure 1.**

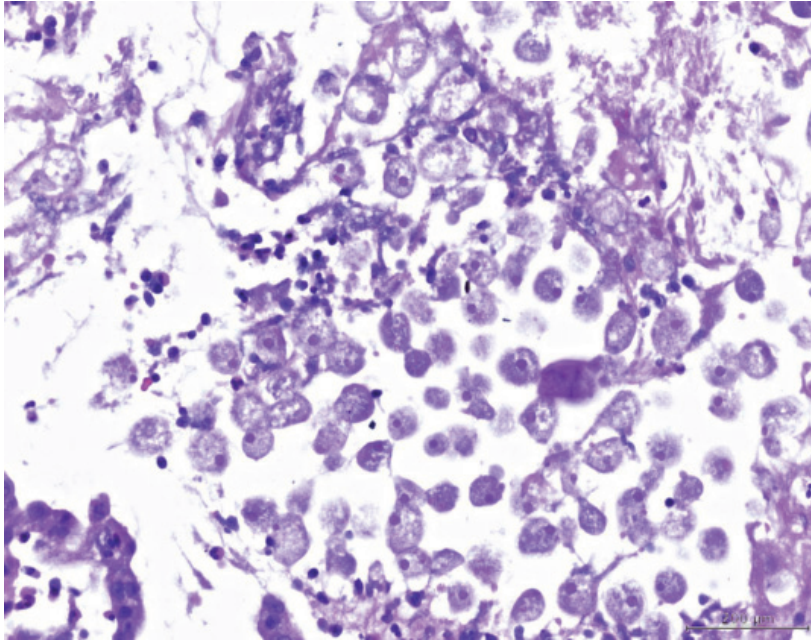


Figure 2.

**What is the most likely diagnosis?**

*(Answer see page 109)*

**Case 2**

A 20-year-old Cambodian male presented with chronic diarrhea with leg edema, HIV testing was non-reactive. The stool tests were initially negative. EGD finding revealed normal. The colonoscopic findings included scalloping appearance, mucosal cracking, and redness of mucosa. The pathology revealed inflamed colonic mucosa with increased eosinophilic infiltration. A worm was identified by its characteristic stichosome, which is muscular oesophagus surrounded by rows of secretory cells called stichocytes (Figure 3).

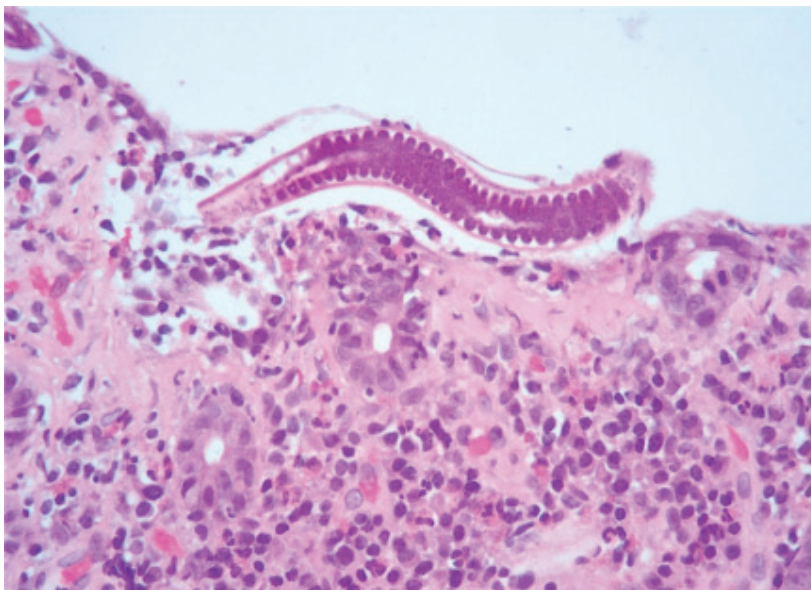


Figure 3.

**What is the most likely diagnosis ?**

*(Answer see page 109)*

Klaikeaw N

### Case 3

A 40-year-old male presented with chronic diarrhea, HIV testing was positive. EGD finding revealed normal. The duodenal biopsies were performed and reported of inflamed small bowel mucosa with dense eosinophilic inflammation containing adult worm, morphologically consistent with *Strongyloides* sp. (Figure 4).

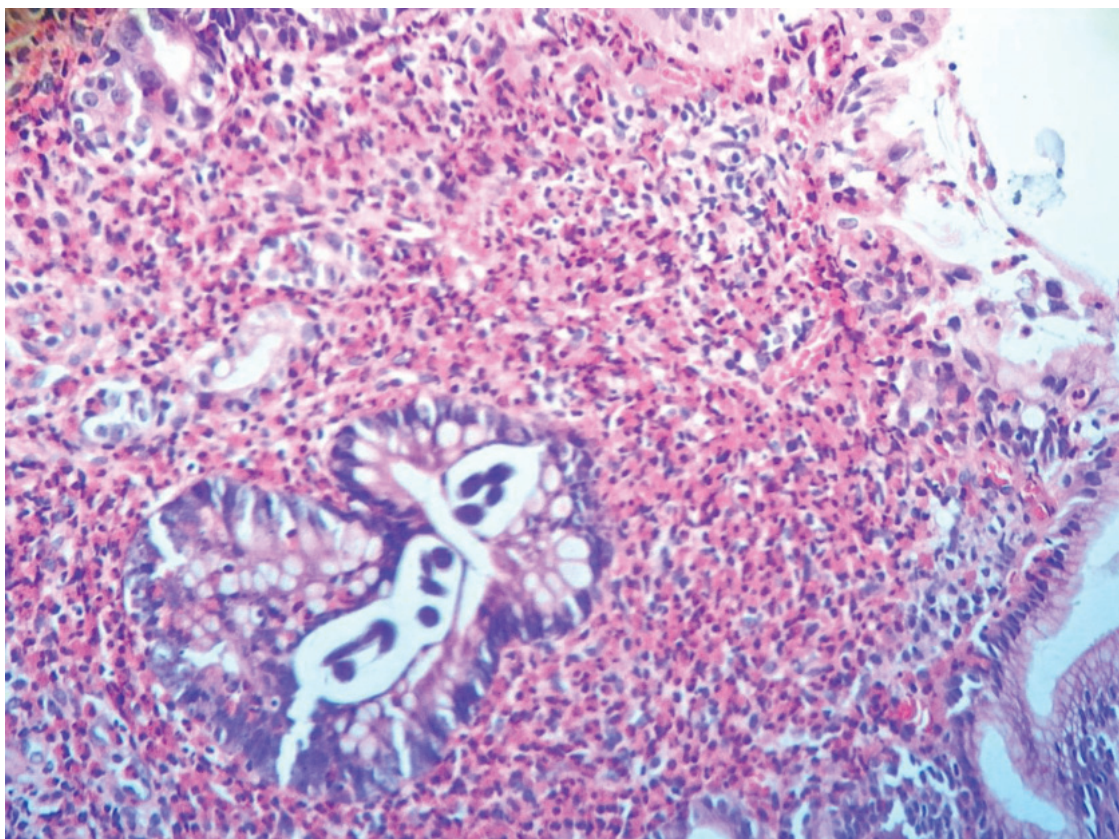


Figure 4.

**What is the most likely diagnosis?**

*(Answer see page 109)*

#### **Answer for patho corner**

Case 1 = Amoebiasis.

Case 2 = Capillariasis.

Case 3 = Strongyloidosis.