

Feasibility of Fujinon Intelligent Color Enhancement (FICE) with Magnification in Differentiating between Diminutive Adenomatous and Hyperplastic Polyps

Sripatoorat P¹
Hongthanakorn C¹
Angchuan S²

ABSTRACT

Background: In Thailand, there are limited data describing the performance of FICE with high magnification for differentiating polyp histology during colon cancer screening. The objective of this study was to evaluate the feasibility of FICE with high magnification for the differentiation of diminutive hyperplastic and adenomatous polyps by using pit patterns observed during real-time colon cancer screening at Bhumibol Adulyadej Hospital.

Patients and Methods: The subjects were 200 patients who underwent colon cancer screening. Pit patterns were applied to predict the histology of 358 polyps which less than 0.6 cm using FICE with high magnification. The feasibility of FICE were calculated and compared with the histopathology as a gold standard.

Results: FICE with high magnification showed sensitivity of 78.7%, specificity of 86.2%, accuracy of 82.1%, PPV of 87.6% and NPV of 76.6% for the discrimination of hyperplastic and adenomatous polyps less than 0.6 cm.

Conclusion: FICE with high magnification provided the acceptable validity scores for discrimination of diminutive polyp histology during colon cancer screening.

Key words : Fujinon Intelligent Color Enhancement (FICE), diminutive polyps.

[*Thai J Gastroenterol 2014; 15(2):86-89.*]

INTRODUCTION

Colorectal cancer is the second most common cause of cancer death in developed countries and most sporadic non-hereditary cases arise from adenomas⁽¹⁾. Colonoscopy with adenoma resection is the promising method for reducing the risk of subsequent colorectal cancer⁽²⁾. More than 90% of polyps detected during

colonoscopy are small (6-9 mm) or diminutive (≤ 5 mm) and diminutive lesion is the most common finding⁽³⁻⁵⁾. Around half of all small polyps are non-neoplastic⁽⁶⁾; therefore, polypectomy is unnecessary and may add the risks during colonoscopy.

The capability to correctly diagnose a polyp during colonoscopy (real-time diagnosis) can leave the

¹Division of Gastroenterology, Department of Internal Medicine and ²Department of Pathology, Bhumibol Adulyadej Hospital, Bangkok, Thailand.

Address for Correspondence: Chanantha Hongthanakorn, M. D., Division of Gastroenterology, Department of Internal Medicine, Bhumibol Adulyadej Hospital, Bangkok, Thailand.

recto-sigmoid hyperplastic polyps and resects or discards small adenomas without confirmation histopathology- possibly leading to substantial savings in time and cost, and reduction in patient risk⁽⁷⁾. Virtual chromoendoscopy imaging with the “Fujinon intelligent color enhancement” system (FICE)⁽⁸⁾ or “narrow-band imaging” (NBI)⁽⁹⁾ is a novel optical approach to enhance mucosal contrast. Both techniques narrow the bandwidth of light components, resulting in dyeless contrast enhancement of mucosal and vascular details. For distinguishing neoplastic from non-neoplastic lesions, FICE was superior to standard colonoscopy and equivalent to conventional chromoendoscopy⁽¹⁰⁾. From a recent study, FICE with high magnification is better for differentiating the histology of small polyps during colon cancer screening than FICE without high magnification, especially for diminutive polyps⁽¹¹⁾.

In Thailand, there are limited data of FICE with high magnification for differentiating polyp histology during colon cancer screening. The objective of this study is to assess the feasibility of FICE with high magnification for the differentiation of diminutive hyperplastic and adenomatous polyps by pit patterns observed during real-time colon cancer screening at Bhumibol Adulyadej Hospital.

MATERIAL AND METHODS

Patients

This prospective study was performed on subjects who attended colorectal cancer screening program at Bhumibol Adulyadej Hospital between January 2013

and December 2013. The exclusion criteria were as follows: familial adenomatous polyposis, prior colorectal surgery, diagnosis of inflammatory bowel disease, melanosis coli, poor bowel preparation, bowel obstruction, severe active gastrointestinal bleeding and allergy to analgesic drug.

The study protocol was approved by the Bhumibol Adulyadej Hospital Ethics Committee for Human Research. Written informed consent was obtained from all enrolled patients.

Endoscopy

Bowel preparation was performed 24 hours before the examination with a low-residue diet followed by the oral administration of 4 L of polyethylene glycol solution. One endoscopist (P.S.) conducted all of the endoscopic procedure in this study. A routine colonoscopy was performed up to the cecum using high-resolution zoom endoscopes (EC 590 ZW; Fujinon, Inc, Saitama, Japan) that provided high-definition on a 19-inch liquid crystal display. The system was equipped with an EPX 4400 processor (Fujinon, Inc) that provided FICE technology. When a polyp was identified, the polyp initially was examined by FICE without high magnification followed by FICE with high magnification. After that, the performing endoscopist made a real-time diagnosis of that polyp (non-adenomatous or adenomatous polyp). The location and size of the polyps were recorded. The size was estimated by biopsy forceps. All polyps were removed by using standard techniques and subsequently evaluated by an experienced pathologist (S.A.) who was blinded to the endoscopic diagnosis. Histologic diagnoses were

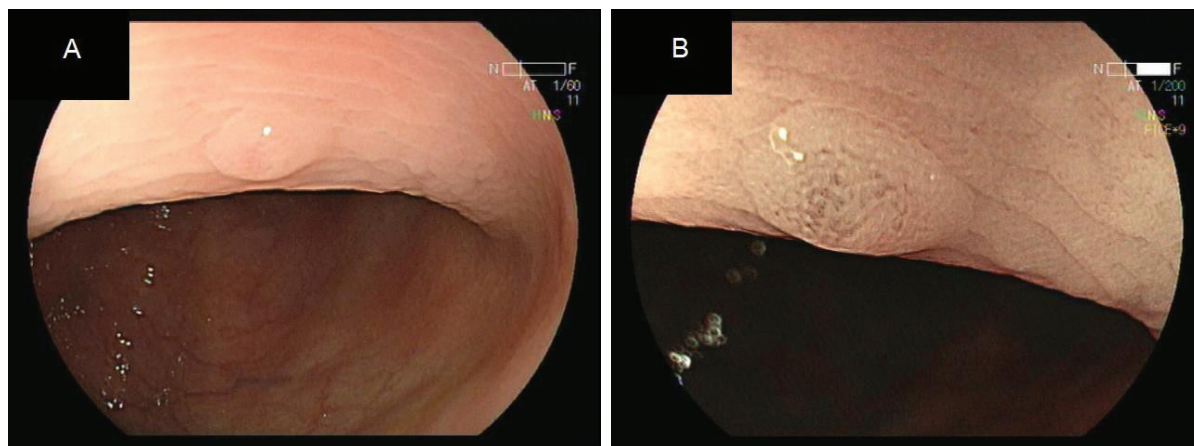


Figure 1. Example of diminutive polyp viewed by FICE. (A) The mucosal surface appearance of polyp by white light without high magnification. (B) FICE with high magnification revealed a tubular pit pattern; Kudo III.

based on World Health Organization criteria. Polyps larger than 5 mm were excluded from the analysis.

Endoscopic criteria for non-adenomatous and adenomatous polyps

The prediction of polyp histology with FICE mode was based on the pit pattern classification defined by Kudo et al.⁽¹²⁾(Figure 1) Polyps were suspected to be non-adenomatous if their surface showed normal or asteroid pit patterns (Kudo types I and II) and suspected to be adenomatous if there were observed by tubular or gyrus-like pit patterns (Kudo types III and IV).

Statistical analysis

The feasibility of FICE with high magnification was determined by comparing the endoscopic diagnoses with the histopathologic diagnoses. Estimation of sensitivity, specificity, accuracy, positive predictive value (PPV) and negative predictive value (NPV) were calculated. Descriptive statistics were used to assess the demographic characteristics. The Kappa value was calculated to measure the interobserver agreement between two interpreters.

Table 1. Demographic characteristics.

Characteristics	Frequency	Percent (%)
Gender (n = 200)		
- Male	96	48
- Female	104	52
Polyp location (n = 358)		
- Cecum	38	10.6
- Ascending	48	13.4
- Transverse	89	24.8
- Descending	36	10.0
- Sigmoid	101	28.2
- Rectum	46	12.8

Table 2. Diagnostic performance of FICE with magnification in the prediction of polyp less than 0.6 cm.

TP	FP	FN	TN	Sensitivity (%)	Specificity (%)	Accuracy (%)	PPV (%)	NPV (%)
156	22	42	138	78.7%	86.2%	82.1%	87.6%	76.6%

TP, true positive, adenoma correctly predicted as adenoma; FP, false positive, non-adenoma incorrectly predicted as adenoma; FN, false negative, adenoma incorrectly predicted as non-adenoma; TN, true negative, nonadenoma correctly predicted as non-adenoma FP, false positive, nonadenoma incorrectly predicted as adenoma; PPV, positive predictive value; NPV, negative predictive value.

RESULTS

A total of 200 patients (mean age, 64 yrs; 104 female) were enrolled, and 358 polyps less than 0.6 cm in size of the patients were analyzed. The mean size of the polyps was 0.4 cm. With respect to location, 137 polyps were found in the right colon (cecum, ascending colon, and transverse colon), 137 were found in the left colon (descending and sigmoid colon), and 46 were found in the rectum (Table 1). A total of 196 (54.7%) of the polyps were adenomatous polyps, whereas 162 (45.2%) of the polyps were non-adenomatous.

The FICE method showed sensitivity of 78.7%, specificity of 86.2%, accuracy of 82.1%, PPV of 87.6% and NPV of 76.6% with high magnification, for differentiation of non-adenomatous and adenomatous polyps less than 0.6 cm (Table 2).

Finally, the interobserver agreement of FICE with high magnification was good (Kappa value = 0.72) for the discrimination of non-adenomatous and adenomatous polyps.

DISCUSSION

Reliable endoscopic colorectal polyps classification can save time, reduce cost and minimize the risk of complications associated with polypectomy. However, especially for diminutive polyps, differentiation of hyperplastic and adenomatous polyps is difficult by white light endoscopy. Therefore, an easy-to-apply endoscopic tool is desirable to improve the determination of polyp histology.

This is the first study in Thailand that evaluate the feasibility of the FICE with magnification for determining diminutive colorectal polyp histology during colon cancer screening. In this study, one endoscopist (GI fellow) prospectively investigated the feasibility of the FICE with high magnification in prediction of polyp histology based on pit patterns.

In the present study, the FICE method showed sensitivity of 78.7%, specificity of 86.2%, accuracy of 82.1%, PPV of 87.6% and NPV of 76.6% with high magnification, for the discrimination of non-adenomatous and adenomatous polyps less than 0.6 cm.

Although the sensitivity, accuracy and NPV of this study were slightly lower than the previous study⁽¹¹⁾, the present study showed similar specificity and PPV. The interobserver agreement of FICE with high magnification was good. These results suggest that FICE with high magnification might be the suitable modality for detailed inspection of diminutive polyps and for prediction of polyp histology.

The present study had several limitations. First, this was a single-institution study so the results may not be applicable to those institutions or endoscopists that have a different set of experiences. Second, the current study did not test whether the Kudo *et al.*⁽¹²⁾ classification was valid for the prediction of polyp histology, which originally was designed for use with chromoendoscopy.⁽¹³⁾ The pit patterns visualized with FICE might not always be identical to those of chromoendoscopy. Further studies are needed to develop a standard for polyp characterization by FICE. Finally, in our study, we did not assess how much additional time is needed for polyp characterization with FICE. Characterizing every diminutive polyp detected with FICE might overburden endoscopists, although the additional time requirement was not long.

CONCLUSION

FICE with high magnification provided the acceptable validity scores for discrimination of diminutive polyp histology during colon cancer screening. It might be the promising modality for discrimination of diminutive polyp histology in the future. Multi-center study is still needed for further evaluation.

REFERENCES

1. Morson B. President's address: the polyp-cancer sequence in the large bowel. *Proc R Soc Med* 1974;67:451-7.
2. Winawer S J, Ho M, O'Brien M J, *et al.* Prevention of colorectal cancer by colonoscopic polypectomy: the National Polyp Study Workgroup. *N Engl J Med* 1993;329:1977-81.
3. Lieberman D, Moravec M, Holub J, *et al.* Polyp size and advanced histology in patients undergoing colonoscopy screening: implications for CT colonography. *Gastroenterology* 2008; 135:1100-5.
4. Chen SC, Rex DK. Endoscopist can be more powerful than age and male gender in predicting adenoma detection at colonoscopy. *Am J Gastroenterol* 2007;102:856-61.
5. Rex DK, Overhiser AJ, Chen SC, *et al.* Estimation of impact of American College of Radiology recommendations on CT colonography reporting for resection of high-risk adenoma findings. *Am J Gastroenterol* 2009;104:149-53.
6. Butterly LF, Chase MP, Pohl H, *et al.* Prevalence of clinically important histology in small adenomas. *Clin Gastroenterol Hepatol* 2006;4:343-8.
7. Ignjatovic A, East JE, Suzuki N, *et al.* Optical diagnosis of small colorectal polyps at routine colonoscopy (Detect InSpect Characterise Resect and Discard; DISCARD trial): a prospective cohort study. *Lancet Oncol* 2009;10:1171-8.
8. Pohl J, May A, Rabenstein T, *et al.* Computed virtual chromoendoscopy (CVC): a new tool for enhancing tissue surface structures. *Endoscopy* 2007;39:80-3.
9. Gono K, Yamazaki K, Doguchi N, *et al.* Endoscopic observation of tissue by narrow band illumination. *Opt Rev* 2003;10:1-5.
10. Pohl J, Lotterer E, Balzer C, *et al.* Computed virtual chromoendoscopy versus standard colonoscopy with targeted indigocarmine chromoscopy: a randomised multicentre trial. *Gut* 2009;58(1):73-8.
11. Kim YS, Kim D, Chung SJ, *et al.* Differentiating small polyp histologies using real-time screening colonoscopy with Fuji Intelligent Color Enhancement. *Clin Gastroenterol Hepatol* 2011;9(9):744-9.e1.
12. Kudo S, Hirota S, Nakajima T, *et al.* Colorectal tumours and pit pattern. *J Clin Pathol* 1994;47:880-5.
13. East JE, Suzuki N, Bassett P, *et al.* Narrow band imaging with magnification for the characterization of small and diminutive colonic polyps: pit pattern and vascular pattern intensity. *Endoscopy* 2008;40:811-7.