

Paracetamol Poisoning: Review of Pathophysiology and Management

Kaikaew K

INTRODUCTION

Paracetamol (Acetaminophen, *N*-acetyl-*p*-aminophenol (APAP)) is an effective nonprescription analgesic and antipyretic which is widely used worldwide, including Thailand. A traditional maximum recommended daily dose is 3-4 g/day, with a maximum single dose of 1 g⁽¹⁾. Nowadays, an FDA advisory panel, in 2009, recommended the lower maximum daily dose of 2.6 g and the maximum single dose of 650 mg⁽²⁾. Few adverse effects occur when using at proper therapeutic dose, but hepatotoxicity can be found with overdose or misuse. In the UK, paracetamol is the most common overdosed medication, 48% of poisoning admissions to hospital, and involved in around 100-200 deaths/year⁽³⁾. Moreover, paracetamol is also a leading cause of acute liver failure requiring liver transplantation in the UK and the US^(4,5). In Thailand, there is an upward trend in pharmaceutical product poisoning⁽⁶⁾. Moreover, paracetamol is the most common substance which is accounted for 17.7% of all acute poison exposure cases presented to the emergency department of a university hospital in Bangkok⁽⁷⁾.

Pathophysiology

Paracetamol is absorbed rapidly by passive diffusion in the stomach and small intestine. The peak plasma concentration, in therapeutic dosage, occurs within 1 hour after ingestion. In the extended-release formulation, the peak plasma level may be achieved in more than 4 hours post ingestion. The elimination half-life, generally, of paracetamol is 2-3 hours. Thus, the recommended dosage interval is 4-6 hours. In the patient with pre-existing liver disease, the half-life of

elimination increased modestly, on average, about 1-2 hours⁽⁸⁾. Currently, a clinically significant overdose, or minimum hepatotoxic dose, is a single ingestion of 10-15 g or 150-250 mg/kg (whichever is lower)^(2, 9).

In the typical therapeutic dose, an average serum concentration of 10-30 µg/mL, paracetamol is mainly metabolized, as shown in Figure 1, by conjugation in the liver, accounted for 60-90% of dose ingested, to form paracetamol glucuronide and sulfate compounds, which are water-soluble nontoxic metabolites and eliminated in the urine. 5-15% of the therapeutic dose is oxidized by mixed-function oxidases, the cytochrome P450 enzyme family, to form highly reactive metabolite, *N*-acetyl-*p*-benzoquinoneimine (NAPQI), the main hepatotoxic substance. NAPQI is rapidly detoxified by glutathione (GSH), and then renally excreted. Less than 5% of paracetamol is unchanged and excreted in the urine⁽¹⁰⁾.

NAPQI, which is a product of phase 1 biotransformation in the liver, is a cytotoxic electrophile that can bind to cellular protein causing various tissue injuries. The reaction is catalyzed by the cytochrome P450 isozymes; that is, CYP2E1, CYP3A4, CYP2A6 and CYP1A2. NAPQI has a significantly short half-life, and reacts, in phase 2 biotransformation, with glutathione, a protective tripeptide (consisting of glutamate, cysteine, and glycine), to form an inactive metabolite, cysteine and mercapturate conjugates⁽¹¹⁾. After overdose or exceed the maximum daily recommended dose, nontoxic sulfatation and glucuronidation may become saturated. Paracetamol, hence, is majorly metabolized by oxidation pathway. Under the conditions that NAPQI formation depletes the glutathione stores to less than 30% of baseline level, NAPQI will

Department of Physiology, Faculty of Medicine, Chulalongkorn University, Bangkok 10330, Thailand.

Address for Correspondence: *Kasiphak Kaikaew, M.D., Department of Physiology, Faculty of Medicine, Chulalongkorn University, Bangkok 10330, Thailand.*

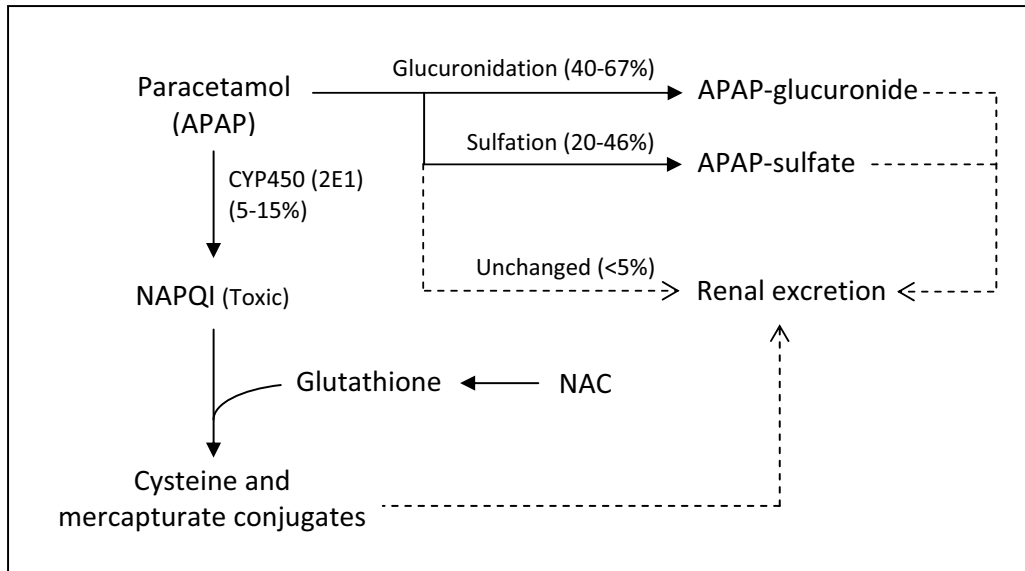


Figure 1. Paracetamol metabolism. APAP: *N-acetyl-p-aminophenol*, NAPQI: *N-acetyl-p-benzoquinoneimine* (main hepatotoxic metabolite), NAC: *N-acetylcysteine*, Dashed line = renal excretion.

covalently bind to sulfhydryl groups and arylate various cellular proteins, resulting in cell deaths and impairments of defense mechanism against endogenous reactive oxygen species⁽¹²⁾. This cascade subsequently causes hepatocellular injury and necrosis, and primarily occurs in centrilobular (zone III) region, where the largest concentration of oxidative metabolism (CYP2E1) is located⁽¹³⁾. Renal failure, which is also found in about 25% of patients with hepatic damage, typically occurs as acute tubular necrosis (ATN). It is proposed to be caused by local production of NAPQI by renal CYP2E1 enzymes; otherwise, several nephrotoxic mechanisms have been established^(10, 12).

The dosage of paracetamol which leads to toxicity may be lower, to 4-6 g, in some settings; that is, GSH depletion (compromised nutritional status, prolonged fasting, acute illness with dehydration, eating disorder, HIV-AIDS), CYP induction (chronic excessive exposure to alcohol, taking enzyme inducing medication, variability in rates of oxidation by cytochrome P450 among populations), and pre-existing liver disease. In addition, the risk of hepatic injury is increased after an overdose in the patients with these mentioned factors^(1, 2, 10, 11).

The early manifestations of paracetamol toxicity, which mostly include nausea and vomiting, and may include malaise and sweating, usually occur within 24 hours after ingestion. Right upper quadrant abdominal pain and tenderness followed by jaundice is the first

indication of hepatic injury. It is usually evident at 24-48 hours and may be delayed up to 4-6 days, while the maximum of hepatic damage usually presents at 72-96 hours from ingestion. Hepatic necrosis and failure are associated with hepatic encephalopathy, altered mental status, coagulopathy, hypoglycemia, metabolic acidosis, and may result in death. Abnormal liver function test is generally detected at 8-24 hours after ingestion⁽¹⁴⁾.

The antidote for paracetamol poisoning, *N-acetylcysteine* (NAC), acts via a number of protective mechanisms. NAC is a precursor for replenishing depleted glutathione level through the generation of intracellular cysteine, since glutathione is necessary for detoxification of NAPQI and protection of protein thiols. NAC may also relieve the saturation of sulfate conjugation during paracetamol overdose⁽¹¹⁾. In addition, NAC promotes microcirculatory blood flow and enhances oxygen delivery to peripheral tissues which associated with decreasing morbidity in established hepatotoxicity⁽¹⁵⁾.

MANAGEMENT

Gastric decontamination by activated charcoal (AC) should be administered in patient with a stable clinical status and arriving the emergency department within 1 hour of ingestion or within 4 hours if concurrent with the medication that decreases gastric empty-

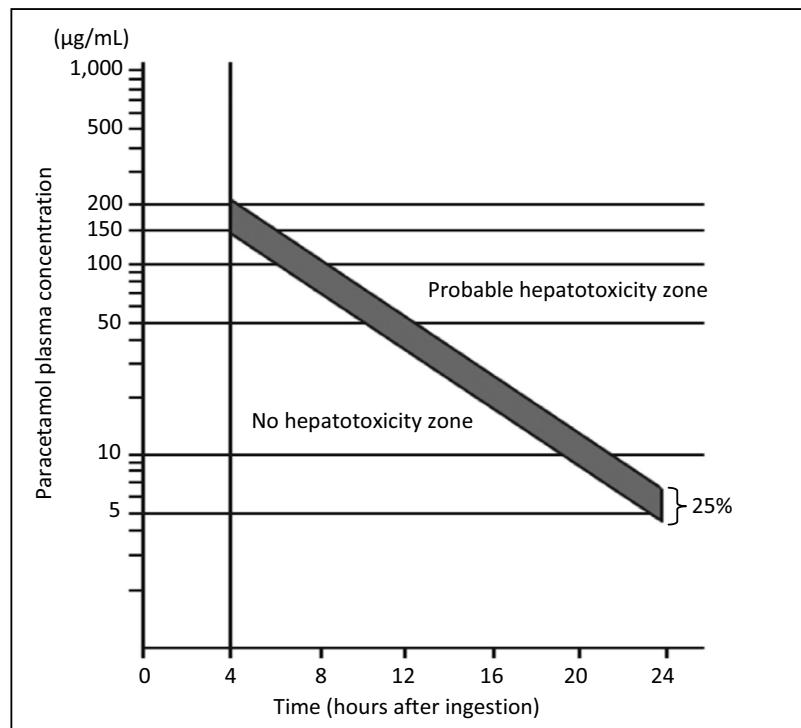


Figure 2. Rumack-Matthew nomogram for single acute acetaminophen ingestion⁽²⁰⁾.

ing. The dosage of AC is 50 g orally (or nasogastrically) as a single dose⁽¹⁶⁾. Although there is an evidence supported that the administration of oral AC later than 4 hours after ingestion can benefit in reducing the incidence of hepatic transaminitis, the effectiveness of gastric decontamination diminishes over time and the clinical benefit is unclear^(17, 18).

Serum paracetamol concentration should be measured at 4 hours after ingestion to determine the risk of hepatotoxicity. Then, plot the value in Rumack-Matthew nomogram (figure 2). If the level is above the possible line, the patient should be admitted to hospital and treated with NAC. If the level is below the possible line for hepatotoxicity, the patient can be safely discharged from hospital⁽¹⁶⁾. Due to the ideally hepatoprotective effect of NAC when it is given within 8 hours after an acute paracetamol overdose, NAC should also be administered in these settings: the patient presents at the hospital close or later than 8 hours after an acute ingestion, the history is unclear but paracetamol toxicity is in suspicion, or the result of paracetamol level cannot be available within 8 hours after ingestion⁽¹⁹⁾.

Semi-logarithmic plot of plasma acetaminophen levels and time after the ingestion. Serum levels before 4 hours may not represent peak levels. This can-

not be used if the time of acute ingestion is unknown. The solid “possible” line 25% below the standard nomogram is included to allow for possible errors in estimated time from ingestion and paracetamol plasma assays.

NAC is the treatment of choice, both oral and intravenous formulations, for paracetamol overdose⁽²¹⁾. The oral regimen starts with a loading dose of 140 mg/kg, followed by 17 doses of 70 mg/kg, given every 4 hours. The total duration of the oral treatment course is 72 hours. The intravenous route is indicated in patients as followed: altered mental status, inability to tolerate oral NAC due to emesis refractory to proper antiemetics, and potential fetal toxicity in a pregnant woman. The intravenous dosage starts with a loading dose of 150 mg/kg infused over 1 hour, followed by 50 mg/kg in over 4 hours, and then 100 mg/kg infused over 16 hours. The total duration of intravenous regimen is 21 hours⁽²²⁾.

Apart from this standard guideline, there are a number of researches intending to identify new adjunctive substances to promote a better clinical outcome in patients with paracetamol-induced liver damage. For instance, in animal models, Aloe vera extract, Curcumin (active ingredient of tumeric), and Genistein are the chemicals which are proved to help attenuate the he-

patic damage⁽²³⁻²⁵⁾. However, further researches are needed to determine whether each medication can be included in the future treatment.

REFERENCES

1. Ferner RE, Dear JW, Bateman DN. Management of paracetamol poisoning. *BMJ* 2011;342.
2. Grosser T, Smyth E, FitzGerald GA. Para-aminophenol Derivatives: Acetaminophen. In: Brunton LL, Chabner BA, Knollmann BC, editors. *Goodman & Gilman's The Pharmacological Basis of Therapeutics*. 12th ed. New York: McGraw-Hill Medical; 2011. p. 982-4.
3. Hawkins LC, Edwards JN, Dargan PI. Impact of restricting paracetamol pack sizes on paracetamol poisoning in the United Kingdom: a review of the literature. *Drug Saf* 2007;30:465-79.
4. Khan LR, Oniscu GC, Powell JJ. Long-term outcome following liver transplantation for paracetamol overdose. *Transpl Int* 2010;23:524-9.
5. Bower WA, Johns M, Margolis HS, Williams IT, Bell BP. Population-based surveillance for acute liver failure. *Am J Gastroenterol* 2007;102:2459-63.
6. Saoraya J, Inboriboon PC. Acute Poisoning Surveillance in Thailand: The Current State of Affairs and a Vision for the Future. *ISRN Emergency Medicine* 2013;2013:9.
7. Limjindaporn C. Acute poison exposure in the emergency department: a 2-year study in a university hospital. *J Med Assoc Thai* 2010;93 Suppl 7:S41-9.
8. McNeil Consumer Healthcare. Briefing Materials for Acetaminophen Advisory Committee Meeting (June 29-30, 2009). U.S. FDA Advisory Committees; 2009.
9. Dart RC, Erdman AR, Olson KR, Christianson G, Manoguerra AS, Chyka PA, *et al.* Acetaminophen poisoning: an evidence-based consensus guideline for out-of-hospital management. *Clin Toxicol (Phila)* 2006;44:1-18.
10. Vale A. Paracetamol (acetaminophen). *Medicine* 2007;35:643-5.
11. Forte JS. Paracetamol: Safety versus Toxicity. *The Chronic ill* 2002:12-6.
12. Hendrickson RG. Acetaminophen. In: Nelson LS, Lewin NA, Howland MA, Hoffman RS, Goldfrank LR, Flomenbaum NE, editors. *Goldfrank's Toxicologic Emergencies*. 9th ed. New York: McGraw-Hill Medical; 2011. p. 483-99.
13. Bessems JG, Vermeulen NP. Paracetamol (acetaminophen)-induced toxicity: molecular and biochemical mechanisms, analogues and protective approaches. *Crit Rev Toxicol* 2001; 31:55-138.
14. Paracetamol. In: Sweetman SC, editor. *Martindale: The Complete Drug Reference*. 36th ed. London: Pharmaceutical Press; 2009. p. 108-12.
15. Harrison PM, Wendon JA, Gimson AE, Alexander GJ, Williams R. Improvement by acetylcysteine of hemodynamics and oxygen transport in fulminant hepatic failure. *New England Journal of Medicine* 1991;324:1852-7.
16. Wallace CI, Dargan PI, Jones AL. Paracetamol overdose: an evidence based flowchart to guide management. *Emerg Med J* 2002;19:202-5.
17. Spiller HA, Winter ML, Klein-Schwartz W, Bangh SA. Efficacy of activated charcoal administered more than four hours after acetaminophen overdose. *J Emerg Med* 2006;30:1-5.
18. Brok J, Buckley N, Glud C. Interventions for paracetamol (acetaminophen) overdose. *Cochrane Database Syst Rev* 2006;Cd003328.
19. Whyte IM, Francis B, Dawson AH. Safety and efficacy of intravenous N-acetylcysteine for acetaminophen overdose: analysis of the Hunter Area Toxicology Service (HATS) database. *Curr Med Res Opin* 2007;23:2359-68.
20. O'Malley GF, O'Malley R. *Acetaminophen Poisoning*. October 2013 ed. New Jersey: Merck Sharp & Dohme; 2013.
21. Cattermole GN. Should N-acetylcysteine be administered orally or intravenously for the treatment of paracetamol overdose? *Hong Kong Journal of Emergency Medicine* 2009;16:106-16.
22. Temple AR, Baggish JS. Guidelines for the Management of Acetaminophen Overdose [Brochure]. Philadelphia: McNeil Consumer and Specialty Pharmaceuticals; 2005 [cited 2014 12 August]. Available from: http://www.tylenolprofessional.com/assets/Overdose_Monograph.pdf.
23. Werawatganon D, Linlawan S, Thanapirom K, Somanawat K, Klaikeaw N, Rerknimitr R, *et al.* Aloe vera attenuated liver injury in mice with acetaminophen-induced hepatitis. *BMC Complement Altern Med* 2014;14:229.
24. Somanawat K, Thong-Ngam D, Klaikeaw N. Curcumin attenuated paracetamol overdose induced hepatitis. *World J Gastroenterol* 2013;19:1962-7.
25. Fan YJ, Rong Y, Li PF, Dong WL, Zhang DY, Zhang L, *et al.* Genistein protection against acetaminophen-induced liver injury via its potential impact on the activation of UDP-glucuronosyltransferase and antioxidant enzymes. *Food Chem Toxicol* 2013;55:172-81.