

Role of Imaging in Hepatocellular Carcinoma

Pantongrag-Brown L

Several imaging modalities become essential in the management of hepatocellular carcinoma (HCC). Three distinct roles of the imaging include:

1. Surveillance test
2. Diagnostic test
3. Assess response to treatment

This article will describe and illustrate the first 2 roles.

Surveillance test

Based on 2010 AASLD guideline, surveillance for HCC should be performed using ultrasound (US)⁽¹⁾. Patients should be screened for 6 months interval, and the surveillance interval does not need to be shortened for patients at higher risk for HCC⁽²⁾. Sensitivity of US

is about 65-80%, and specificity is about 90%⁽³⁾. However, sensitivity and specificity of US are lower in diffuse nodular cirrhotic livers, and in obese patients with fatty liver and cirrhosis⁽⁴⁾. In spite of some weakness, US is superior to any of the serological tests, and is a recommendation of choice for surveillance for HCC. Nodules detected by US could be hypo-echoic, hyper-echoic, or mixed-echoic patterns (Figure 1). Once the nodule of at least 1 cm is detected by US, it needs confirmation by other diagnostic test.

Diagnostic test

Non-invasive imaging modalities for diagnosis of early HCC include:

1. Contrast-enhanced US

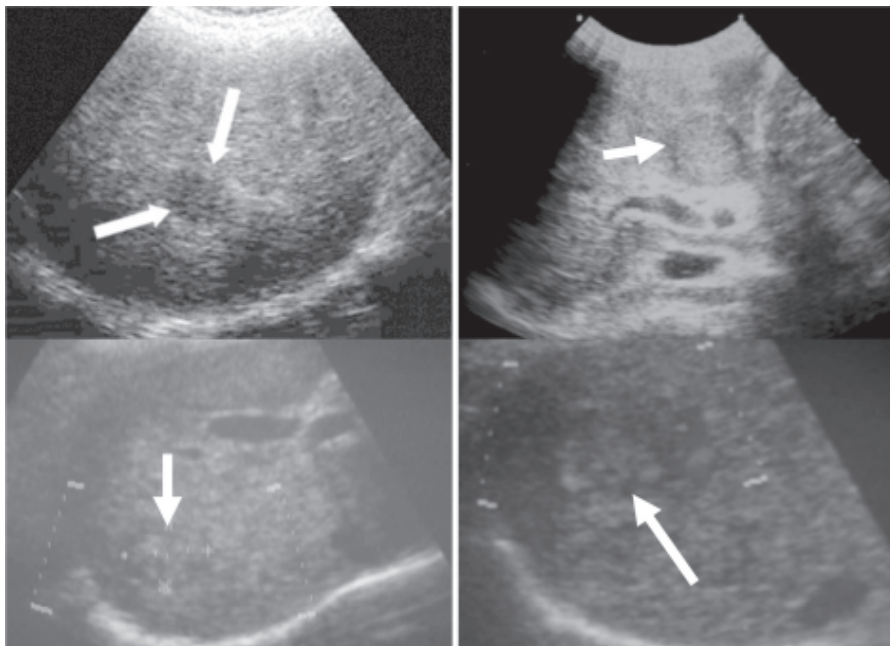


Figure 1. Nodules detected by US could be hypo-echoic, hyper-echoic, or mixed-echoic patterns. These nodules need confirmation by other diagnostic test.

Advanced Diagnostic Imaging Center, Ramathibodi Hospital, Bangkok, Thailand.

Address for Correspondence: *Linda Pantongrag-Brown, MD, Advanced Diagnostic Imaging Center, Ramathibodi Hospital, Bangkok, Thailand.*

Pantongrag-Brown L

2. Multiphasic-multislice CT (MDCT)
3. MRI with extracellular (EC) contrast
4. MRI with hepatocyte-specific contrast (EOB-primovist)

Based on 2010 AASLD guideline, 4 phase-MDCT or dynamic EC contrast enhanced MRI is the imaging of choice for diagnosis of HCC⁽¹⁾. Classic appearance for diagnosis of HCC includes nodules that show arte-

rial enhancement and venous or delayed washout (Figure 2, 3). Based on this typical enhancement pattern, treatment could be initiated without a need for tissue biopsy. However, this classic enhancement pattern is existed in less than 50%⁽⁵⁾. If we strictly follow the guideline, there will be too many cases to biopsy, which is not practical in a high prevalent area like Thailand. Fortunately, the Japanese guideline has introduced

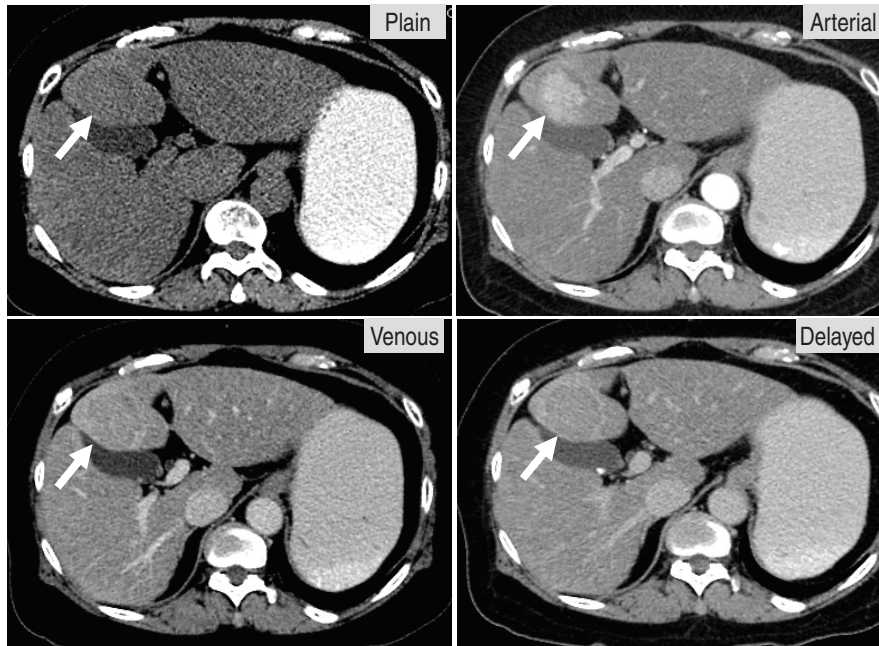

Figure 2. Multiphase multislice CT shows arterial enhancement, venous and delayed washout, characteristic for HCC.

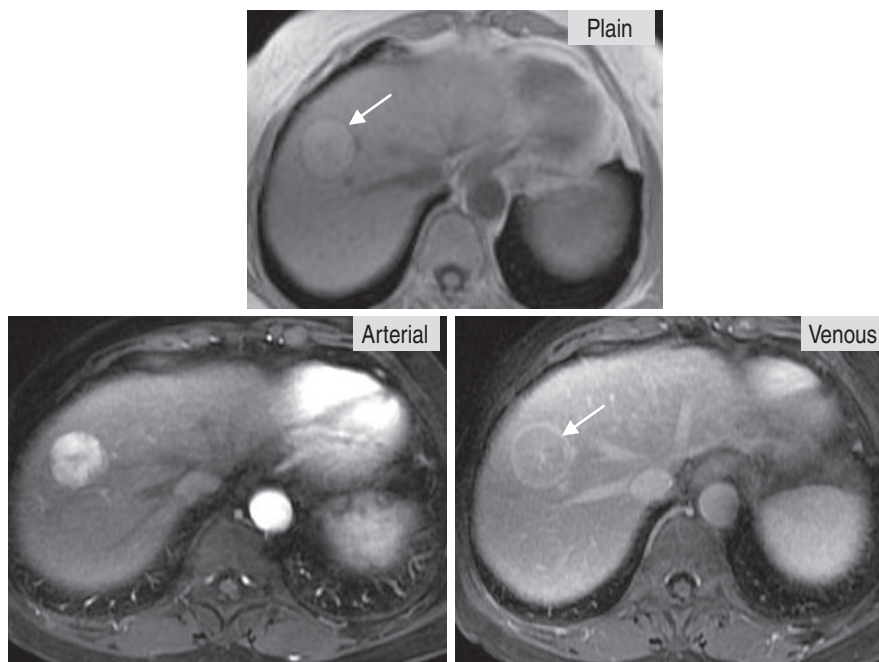


Figure 3. MRI with extracellular contrast agent shows arterial enhancement, and rapid venous washout, which is characteristic for HCC. Also note a thin capsule of HCC (arrow).

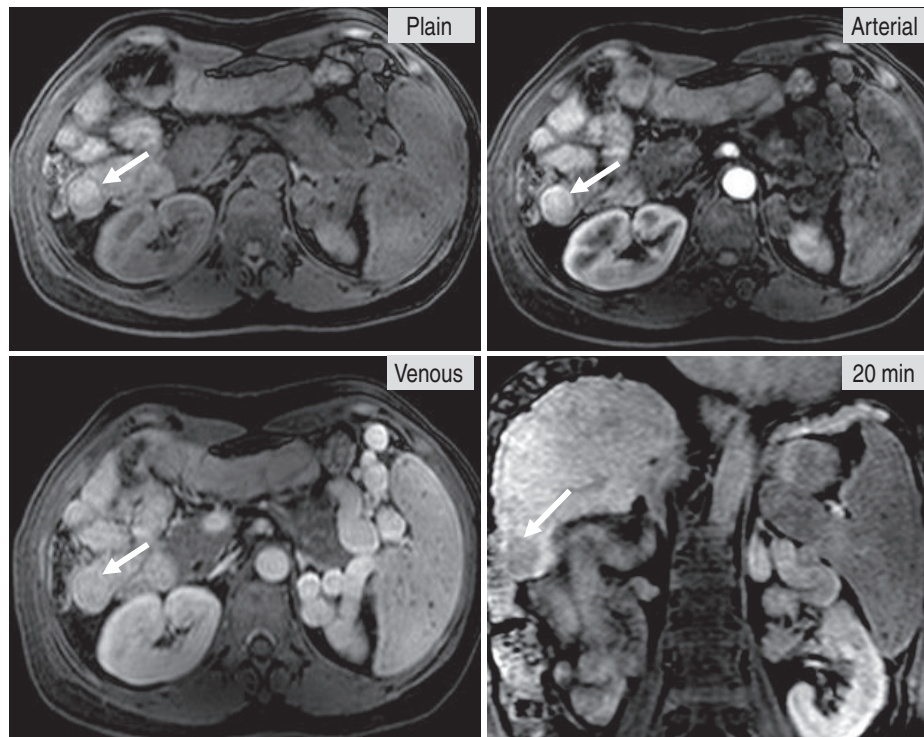


Figure 4. MRI with EOB-primovist contrast agent shows arterial enhancement, but iso-venous washout, which is not diagnostic for HCC, based upon the AASLD guideline. However, at 20 min hepatobiliary (HB) phase, the nodule shows no uptake of primovist. Based upon the Japanese guideline, a combination of arterial enhancement with no primovist uptake is characteristic for HCC regardless of venous phase.

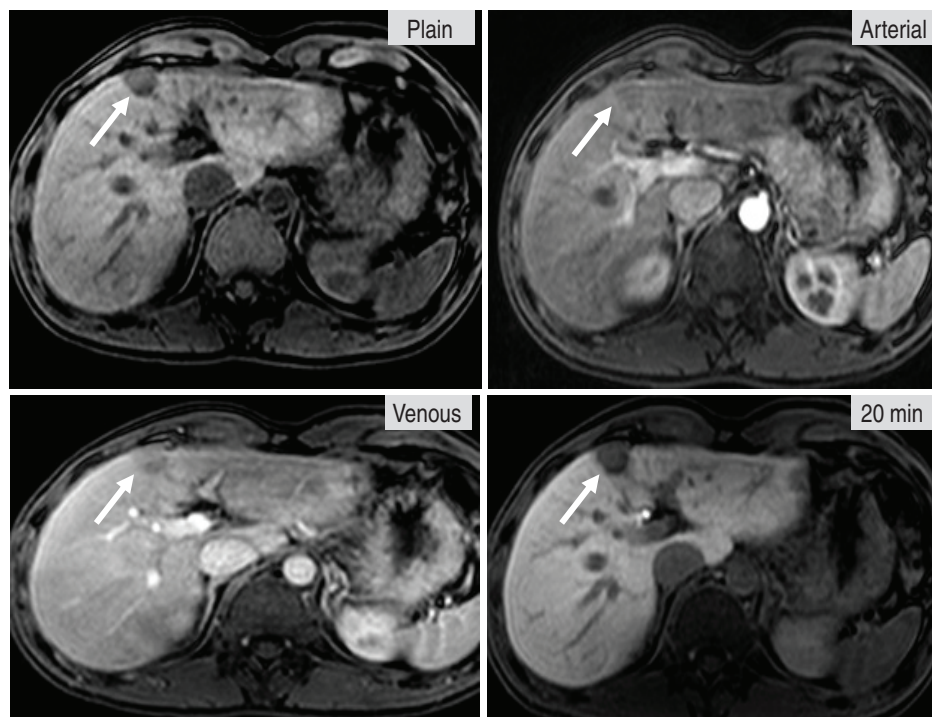


Figure 5. A 2 cm hypovascular HCC in a patient with chronic HBV. MRI with EOB-primovist contrast agent shows a hypovascular nodule, which is atypical for HCC. Because of its atypical pattern, tissue biopsy is required to confirm the diagnosis.

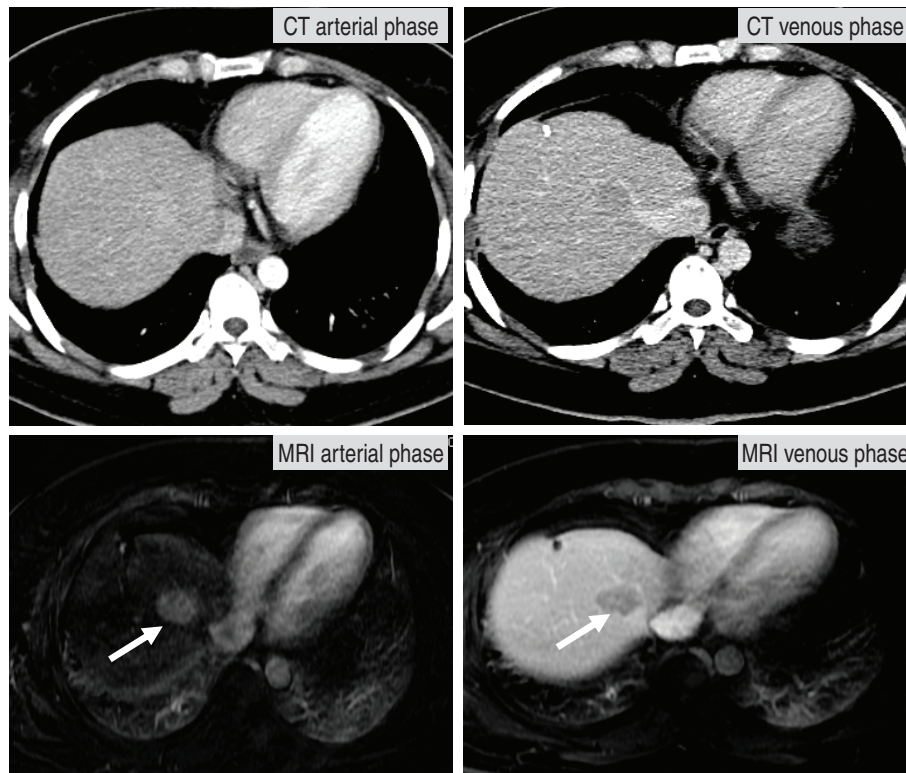


Figure 6. A 39-year-old female, S/P left hepatectomy for HCC, presenting with rising AFP. CT was first performed and missed the lesion. MRI was later able to detect a liver nodule, showing arterial enhancement and venous washout, typical for a new focus of HCC.

MRI with EOB-primovist for these suspicious nodules⁽⁶⁾. Nodules that show arterial enhancement and no uptake of EOB-primovist are considered diagnostic for HCC, regardless of venous washout (Figure 4). Applying both guidelines help expanding the diagnosis of HCC with high accuracy and less tissue biopsy.

Some nodules are relatively hypovascular. The approach to these nodules is problematic without clear guideline. The Japanese group suggests biopsy of nodules that are > 1.5 cm, based on natural history that nodules of this size tend to increase over time (Figure 5)⁽⁷⁾. Hypovascular nodules of less than 1.5 cm could be follow-up.

Which imaging modality is the best for HCC diagnosis?

MRI is usually the better imaging modality than CT for detection and characterization of liver mass (Figure 6). This is because MRI could assess both tissue characteristics and vascular enhancement pattern, whereas CT could assess only vascular pattern of the mass. Moreover, high radiation dose of CT precludes short interval follow-up. Regarding MRI contrast me-

dia, hepatobiliary specific contrast agent (EOB-primovist) has a better benefit than conventional extracellular contrast agent. This is because EOB-primovist has 2 properties of vascular enhancement and functional hepatocyte uptake, whereas conventional contrast agent has only one property of vascular enhancement. However, interpretation of MRI with EOB-primovist is complexed and usually radiologist specialized in liver imaging is required for accurate assessment.

Take home message:

1. Imaging has 3 roles in HCC; surveillance, diagnosis and assessment of treatment.
2. US is the imaging of choice for surveillance, and superior to any of the serological test.
3. Both contrast-enhanced MDCT and MRI are recommended for diagnosis of HCC, once significant nodules are detected by US.
4. MRI with hepatobiliary specific contrast agent may help decrease the rate of tissue biopsy, compared to MRI with conventional contrast agent.

REFERENCES

1. Bruix J, Sherman M. Management of hepatocellular carcinoma: an update. *Hepatology* 2011;53:1020-2
2. Zhang BH, Yang BH, Tang ZY. Randomized controlled trial of screening for hepatocellular carcinoma. *J Cancer Res Clin Oncol* 2004;130:417-22
3. Bolondi L, Sofia S, Siringo S, *et al.* Surveillance programme of cirrhotic patients for early diagnosis and treatment of hepatocellular carcinoma: a cost effectiveness analysis. *Gut* 2001; 48:251-9
4. Chen TH, Chen CJ, Yen MF, *et al.* Ultrasound screening and risk factors for death from hepatocellular carcinoma in a high risk group in Taiwan. *Int J Cancer* 2002;98:257-61
5. Yoon SH, Lee JM, So YH, *et al.* Multiphase MDCT enhancement pattern of hepatocellular carcinoma smaller than 3 cm in diameter: tumor size and cellular differentiation. *AJR Am J Roentgenol* 2009;193:W482-489
6. Kudo M. Management of hepatocellular carcinoma: from prevention to molecular targeted therapy. *Oncology* 2010;78 (suppl 1):1-6
7. Sakamoto M, Hirohashi S. Natural history and prognosis of adenomatous hyperplasia and early hepatocellular carcinoma: multi-institutional analysis of 53 nodules followed for more than 6 months and 141 patients with single early hepatocellular carcinoma treated by surgical resection or percutaneous ethanol injection. *Jpn J Clin Oncol* 1998;28:604-8.