

Imaging of Gastrointestinal Stromal Tumors (GISTs)

Pantongrag-Brown L

GISTs are the most common mesenchymal tumors of the GI tract. It is believed that GISTs arise from interstitial cells of Cajal, which are considered gut pacemakers⁽¹⁾. GISTs may occur anywhere in GI tract, mesentery, omentum, and retroperitoneum. However, majority of GISTs occur in the stomach, and small bowel⁽²⁾. GISTs are highly malignant potential and none can be labeled definitely as benign⁽³⁾. In this article, imaging of GISTs along the GI tract is illustrated.

Gastric GISTs

Stomach is the most common site for GISTs, found in almost 50% of cases⁽⁴⁾. Imaging findings include submucosal mass (Figure 1), exophytic growth with cavitation and necrosis (Figure 2). Calcification may occur, but uncommon⁽⁴⁾. Differential diagnosis includes submucosal benign tumors such as lipoma (Figure 3), and schwannoma; and malignant tumors such as neuroendocrine tumor (NET) (Figure 4), lymphoma, and gastric cancer (Figure 5). Lack of lymphadenopathy helps differentiate GIST from lymphoma or gastric cancer.

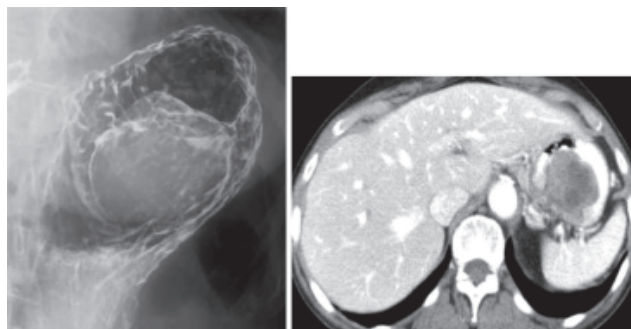


Figure 1. Gastric GIST

UGI study and CT show a submucosal mass at gastric fundus.

Small bowel GIST

Small bowel is the second most common site for GISTs after stomach, found in almost 20% of cases⁽⁴⁾. Small bowel GISTs are usually more aggressive than gastric GISTs. Jejunum is most commonly involved, followed by duodenum, and ileum⁽⁴⁾. Imaging findings

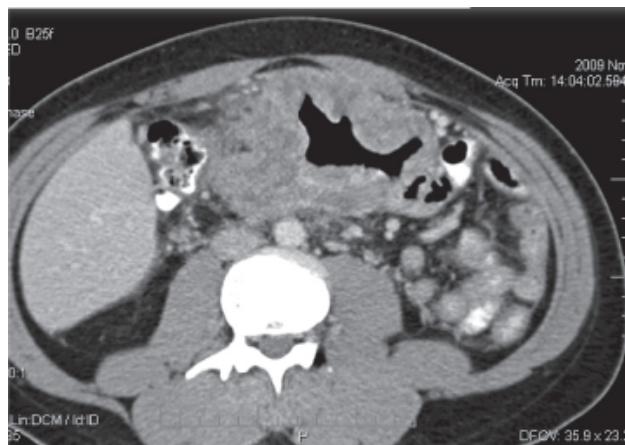

Figure 2. Gastric GIST

CT shows exophytic growth from the gastric wall with cavitation and necrosis.

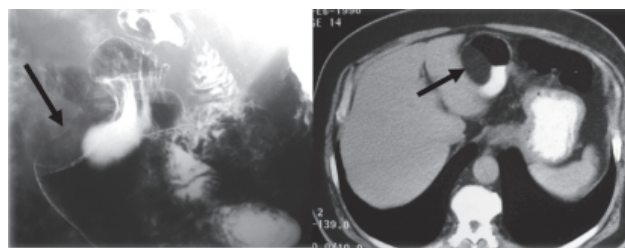


Figure 3. Lipoma

UGI study shows a submucosal mass of the gastric antrum, mimicking gastric GIST. However, CT shows a fatty mass, consistent with a lipoma.

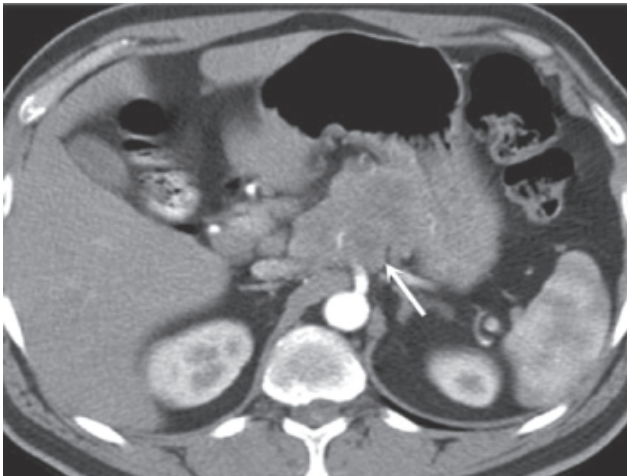

Figure 4. Gastric NET

CT shows exophytic growth from the gastric wall, mimicking gastric GIST. However, surgical pathology confirms diagnosis of NET.

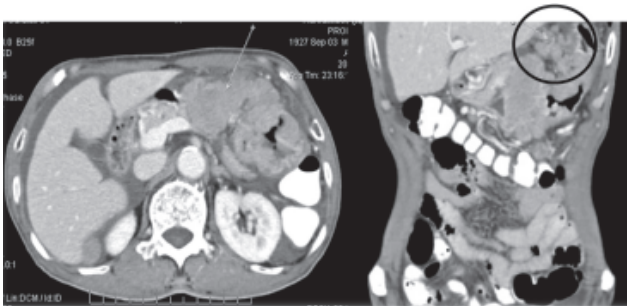


Figure 5. Gastric adenocarcinoma

CT axial view shows exophytic mass from the gastric wall, mimicking gastric GIST. However, CT coronal view shows lymphadenopathy which is not characteristic for GIST. Histopathology confirms the diagnosis of gastric cancer.

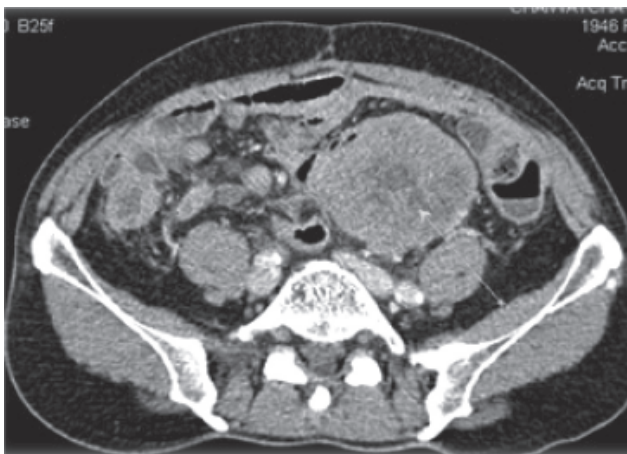


Figure 6. Small bowel GIST

CT shows exophytic growth from the wall of the small bowel.

include submucosal mass (Figure 6), exophytic growth with cavitation and necrosis. Aneurysmal dilatation is the termed often described small bowel mass with cavitation (Figure 7)⁽⁵⁾. Differential diagnosis includes lymphoma (Figure 8), leiomyosarcoma, adenocarcinoma (Figure 9), and metastasis (Figure 10). Lack of adenopathy is a hallmark for GISTs, which helps differentiating them from other malignant tumors.

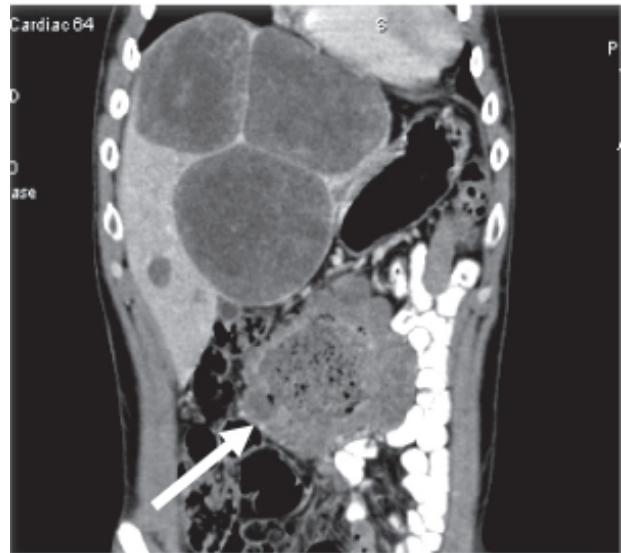

Figure 7. Small bowel GIST with liver metastasis

CT shows exophytic mass with cavitation and necrosis of the small bowel. This pattern is often described as “aneurysmal dilatation”. Multiple necrotic liver metastases suggest aggressive behavior of the tumor.

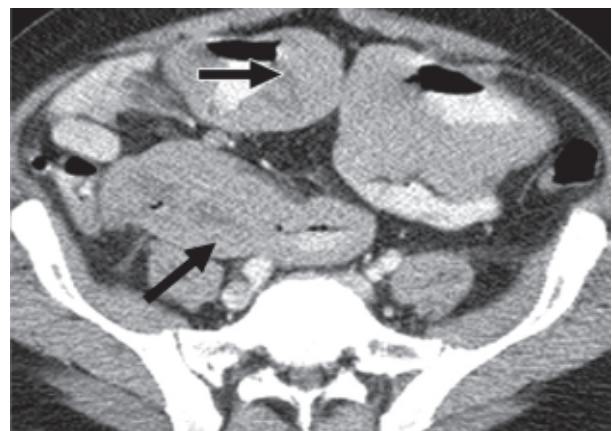


Figure 8. Small bowel lymphoma

CT shows aneurysmal dilatation of the small bowel, mimicking GIST. However, the abnormality involves several small bowel loops, making lymphoma a favorable diagnosis.

Linda Pantongrag-Brown.

Anorectal GISTs

Anorectal junction is the third most common site for GISTs, after stomach and small bowel⁽⁴⁾. Majority of anorectal GISTs are aggressive. Imaging findings include mural mass that expands the rectal wall (Figure 11). Sometimes, the mass could extend into the ischiorectal fossa, prostate gland, or vagina⁽⁶⁾. Differential diagnosis includes lymphoma (Figure 12), and NET (Figure 13).

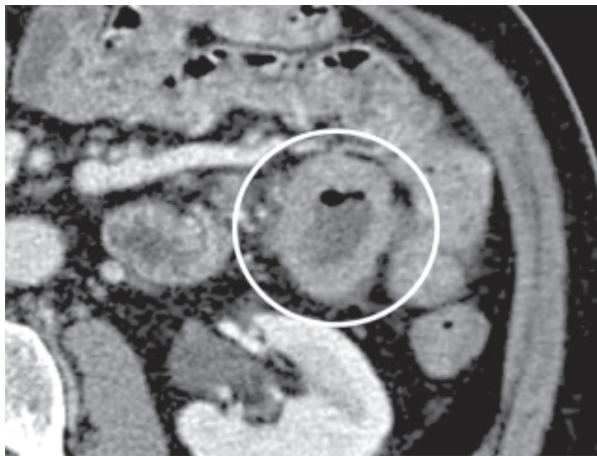


Figure 9. Small bowel adenocarcinoma

CT shows aneurysmal dilatation of the small bowel, mimicking GIST. However, surgical pathology proves the lesion to be small bowel adenocarcinoma.

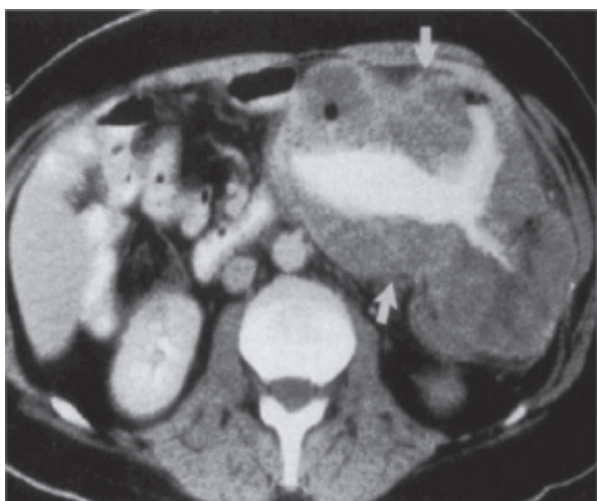


Figure 10. Small bowel metastasis from malignant melanoma

CT shows a large aneurysmal dilatation of the small bowel, mimicking GIST. However, this patient has a history of malignant melanoma and this abnormality is proved to be metastasis.

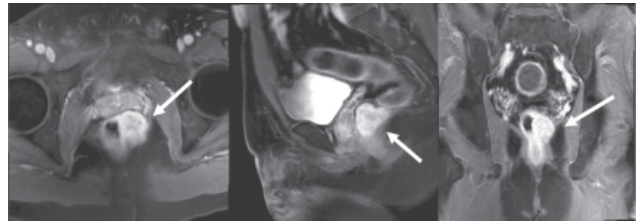


Figure 11. Rectal GIST

MRI shows a hypervascular submucosal mass at the left lateral wall of the rectum.

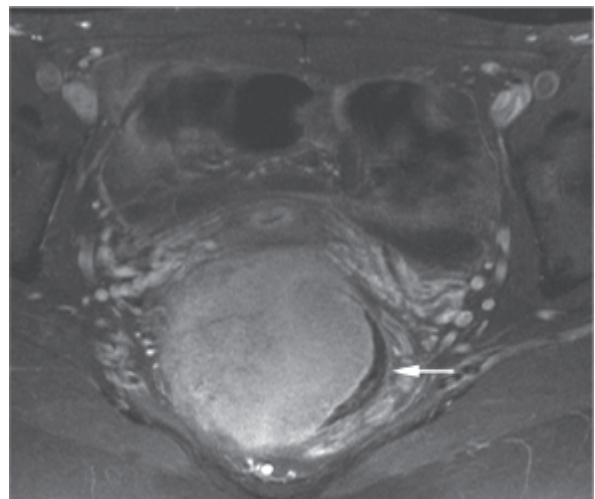


Figure 12. Rectal lymphoma

MRI shows a large submucosal mass of the rectum, mimicking GIST. However, histopathology is proved to be lymphoma.

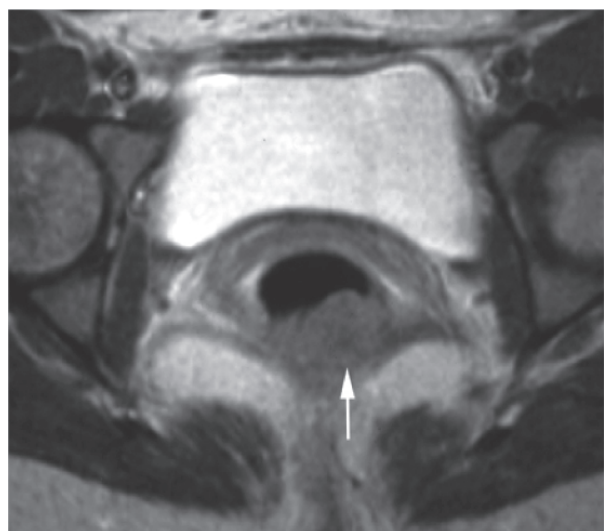


Figure 13. Rectal NET

MRI shows a submucosal mass of the rectum, mimicking GIST. However, histopathology is proved to be NET.

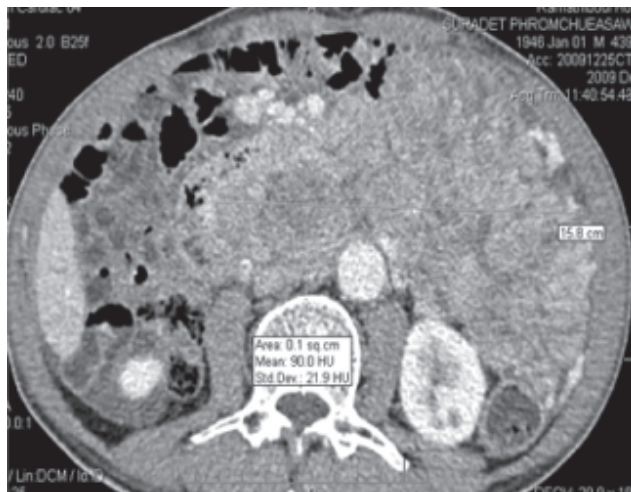

Figure 14. Mesenteric GIST

CT shows a large irregular mass locating mainly within the small bowel mesentery.

GISTs of Colon, Esophagus, and Mesentery/Omentum

Colon, esophagus, mesentery, and omentum are uncommon sites for GISTs⁽⁴⁾. Imaging findings of colonic and esophageal GISTs are similar to other GI tract sites, which include mural or submucosal mass, and exophytic growth with cavitation and necrosis. Imaging of mesentery/omentum GISTs include well-defined or irregular masses associated with necrosis and hemorrhage⁽⁷⁾ (Figure 14), similar to other sarcomas.

Conclusions:

1. GISTs usually originate from muscularis propria of the GI tract and extend both inside and outside of the bowel lumen.

2. Submucosal mass and exophytic growth with cavitation and necrosis (aneurysmal dilatation) are common imaging findings.

3. Lack of adenopathy is characteristic for GISTs.

4. Differentiation from other mural tumors is difficult, and eventually histology with immunohistochemical stains is required.

REFERENCES

1. Nishida T, Hirota S. Biological and clinical review of stromal tumors in the gastrointestinal tract. *Histol Histopathol* 2000; 15:1293-301.
2. Hong X, Choi H, Loyer EM, *et al.* Gastrointestinal stromal tumor: role of CT in diagnosis and in response evaluation and surveillance after treatment with Imatinib. *RadioGraphics* 2006; 26:481-95.
3. Miettinen M, El-Rifai W, Sobin LH, *et al.* Evaluation of malignancy and prognosis of gastrointestinal stromal tumors: a review. *Hum Pathol* 2002; 33:478-83.
4. Levy A, Remotti HE, Thompson WM, *et al.* Gastrointestinal stromal tumors: radiologic features with pathologic correlation. *RadioGraphics* 2003; 23:283-304.
5. Pantongrag-Brown L. Aneurysmal dilatation of the small bowel. *Thai J Gastroenterol* 2009; 10:111-3.
6. Hasegawa S, Semelka RC, Noone TC, *et al.* Gastric stromal sarcomas: correlation of MR imaging and histopathologic findings in nine patients. *Radiology* 1998; 208:591-5.
7. Miettinen M, Monihan JM, Sarlomo-Rikala M, *et al.* Gastrointestinal stromal tumors/smooth muscle tumors (GISTs) primary in the omentum and mesentery: clinicopathologic and immunohistochemical study of 26 cases. *Am J Surg Pathol* 1999; 23:1109-18.