

## The Accuracy of Diagnosis of *Helicobacter pylori* Infection in Patient with Dyspepsia by Fujinon Intelligent Chromo Endoscopy (FICE) at Srinagarind Hospital

Phuphatham A<sup>1</sup>  
Sangchan A<sup>1</sup>  
Kularbkaew J<sup>2</sup>

### ABSTRACT

**Background:** *Helicobacter pylori* is a spiral gram negative bacteria etiologically linked to several medical conditions. More than one half of world's populations had been infected, particularly in developing countries. Recently, The Fujinon Intelligent Chromo Endoscopy (FICE), which demonstrated the regular arrangement of collecting venules patterns (RAC), is a new modality to diagnose *H. pylori* infection. The objective of this study is to determine the accuracy of the arrangement of collecting venules pattern for diagnosis of *H. pylori* infection.

**Patients and Methods:** Fifty eight patients with dyspepsia were evaluated by esophagogastroduodenoscopy (EGD) and FICE. The images of collecting venules pattern were recorded at the fundus and lesser curvature. Additionally, the gastric biopsies were obtained. The presence of *H. pylori* infection was determined by rapid urease test or histology. The sensitivity and specificity of the collecting venules pattern in diagnosis of *H. pylori* infection was evaluated.

**Results:** *H. pylori* was detected in 28 patients (48%). The RAC negative pattern provided 89.2% sensitivity and 70% specificity in diagnosis of *H. pylori* infection in patients with dyspepsia. The negative predictive value (NPV) and the positive predictive value (PPV) were 87.5% and 73.5% respectively. In addition, the overall validity was 79.3%.

**Conclusion:** The abnormal arrangement of collecting venules near incisura angularis of the stomach provided the acceptable sensitivity and negative predictive value in diagnosis of *H. pylori* infection in patients with dyspepsia. It could be used as a screening test for *H. pylori* infected gastric mucosa.

**Key words :** *Helicobacter pylori*, dyspepsia, Fujinon Intelligent Chromo Endoscopy

[*Thai J Gastroenterol* 2012; 13(2): 68-72.]

<sup>1</sup>Division of Gastroenterology, Department of Medicine, <sup>2</sup>Department of Pathology, Faculty of Medicine, Khon Kaen University, Khon Kaen

**Address for Correspondence:** Apichat Sangchan, M.D., Department of Gastroenterology, Faculty of Medicine, Khon Kaen University, Khon Kaen, Thailand.

## INTRODUCTION

*Helicobacter pylori* is a noninvasive, slow-growing, microaerophilic, highly motile, gram negative bacterium that habitat in the human stomach. It is one of the major etiologies of gastrointestinal tract disease such as chronic gastritis, peptic ulcer disease (PUD), and gastric carcinoma. Furthermore it is associated with the extra gastric conditions including iron deficiency anemia and immune thrombocytopenic purpura<sup>(1)</sup>. More than one half of the world's population had been infected by *H. pylori*, particularly in developing countries. In Thailand, the prevalence of *H. pylori* infection is 48.2%. However it varies between the regions. In the Northeast region, the prevalence of *H. pylori* infection is 67.1 %, which is the highest<sup>(2)</sup>.

Several trials aimed to distinguish *H. pylori* positive gastritis from *H. pylori* negative normal stomach by using esophagogastroduodenoscopy (EGD) to assess collecting venules pattern in the stomach. The collecting venules are minute red points on gastric mucosa but in closed view or magnified view it looks like a star fish. The regular arrangement of collecting venules (RAC) which is a regular distribution of the collecting venules on gastric mucosa is characteristic of a normal gastric mucosa without *H. pylori* infection<sup>(3,4)</sup>. Many investigators used magnifying endoscopy to observe the RAC and they can discriminate the normal gastric mucosa from the *H. pylori* gastritis<sup>(5-7)</sup>. However, the other studies that used the conventional endoscopy to assess the RAC can also do<sup>(8,9)</sup>. The Fujinon Intelligent Chromo Endoscopy (FICE) is a computed virtual chromoendoscopy which enhancing visualization of vascular structure of mucosa and it can demonstrate the normal mucosa of the gastric corpus by visualization of the RAC<sup>(10)</sup>.

The objective of this study is to reveal the accuracy of diagnosis of *H. pylori* infection in patient with dyspepsia by using the FICE without magnification.


## MATERIAL AND METHODS

### Patients

This study was approved by the Khon Kaen University Ethics Committee for Human Research. The populations of this study were calculated according to diagnostic test. The 58 patients, all aged over 18 years who presented with dyspepsia underwent EGD at the endoscopic unit of Srinakarind Hospital between June 2009 and January 2010 were enrolled in the study. All of them had no previous *H. pylori* eradication within one year as well as no previous medication such as NSAIDs, proton pump inhibitor (PPI), and antibiotics (e.g. amoxicillin, bismuth compound drug) within one month before enrolling to the study. Besides, Patients with history of gastrointestinal bleeding or bleeding diathesis including liver cirrhosis and inflammatory bowel disease were excluded. All patients were asked to give signed informed consent before entering the study.

### Endoscopy

We used standard adult gastroscopy (Fujinon EG590WR) with a video processor & light source of Fujinon system 4400, in which the wave length of light was set according to Arved W. Schneider *et al*<sup>(10)</sup>. All procedures were performed by the same endoscopist in each patient. After the standard EGD was complete, the arrangement of collecting venules pattern at gastric fundus and lesser curvature of gastric body near incisura angularis were evaluated by the FICE<sup>(8)</sup>. These



**Figure 1.** Gastric mucosa at the lesser curvature showed (A) the regular arrangement of collecting venules pattern (RAC), (B) the irregular arrangement of collecting venules pattern (IAC), and (C) the obscured arrangement of collecting venules pattern (OAC).

were classified into three patterns: (1) the regular arrangement of collecting venules pattern (RAC), (2) the irregular arrangement of collecting venules pattern (IAC), and (3) the obscured arrangement of collecting venules pattern (OAC). The first and the two latter were called the positive and negative RAC patterns, respectively (Figure 1). The images were obtained as well. This was done after aspirating gastric content and washing gastric mucosa with 0.9% NSS if necessary. The gastric tissues were collected from gastric antrum, and body for rapid urease test and histology.

The collecting venules pattern of all patients were interpreted by another endoscopist who was blinded to the endoscopic result, rapid urease test and the histology at the same time after ending of the study.

### Rapid urease test

We used a commercial kit (Pronto dry<sup>®</sup>) which is distributed by Eisai Thailand Marketing Co.Ltd.

### Histology

Gastric antrum and body biopsy specimens were carefully placed on filter paper, and fixed in 10% formalin. These were colored with H&E stain and with Warthin-Starry stain if the former had no demonstration of *H. pylori*. All histology was interpreted by the same pathologist who was blinded to the rapid urease test and endoscopic results.

For this study, the standard for diagnosis of *H. pylori* infection was either the rapid urease test or positive histological result.

### Statistical analysis

The sensitivity (Sens.), specificity (Spec.), negative predictive value (NPV), positive predictive value (PPV) and overall validity were used to assess the accuracy of the collecting venules pattern in patients with dyspepsia and possibly infected by *H. pylori*. Descriptive statistics were used to assess the demographic characteristics. The Kappa value was calculated to measure the interobserver agreement between two interpreters.

## RESULTS

A total of 58 patients were enrolled in the study. The EGD revealed that the majority of them had only gastritis (40 in 58). However the severity of this gastritis was almost always mild. There were also normal

Table 1. Demographic characteristics.

Characteristics	Frequency (n = 58)	Percent (%)
Gender (male:female)	25:33	43.1:56.9
Age (yrs)	25-78 (mean 48)	
Endoscopic findings		
- Normal	11	19
- Gastritis	40	70
- Gastritis with GERD	3	5
- Gastroduodenitis	3	5
- Gastritis with lipoma	1	1
Pathology		
- Mild to moderate gastritis	53	91.4
- Chronic gastritis with intestinal metaplasia	5	8.6

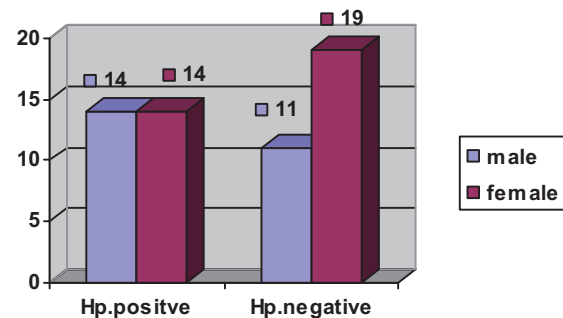
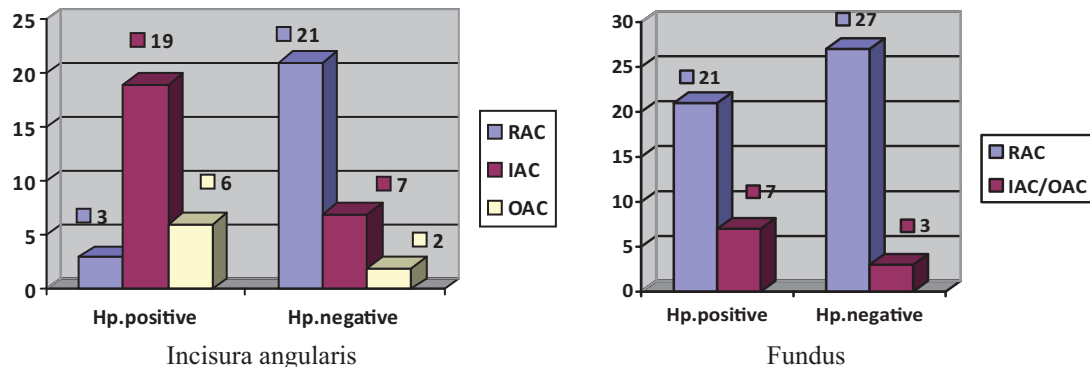


Figure 2. *H. pylori* infection classified by gender.

EGD findings (11 in 58). Nonetheless all pathology revealed mild to moderate chronic gastritis. Additionally, there were three patients had both gastritis and GERD, another three had gastroduodenitis and only one had both gastritis and lipoma (proven by EUS) at antrum of stomach (Table 1).

*H. pylori* infection was diagnosed in 28 patients with no gender differences. This present study showed the prevalence of *H. pylori* infection to be 48% (Figure 2).

The positive RAC pattern at lesser curvature near incisura angularis of the stomach was observed in 24 patients; 70% (21 in 30) of *H. pylori* negative patients and 10.71% (3 in 28) of *H. pylori* positive patients. The negative RAC (either IAC or OAC) pattern was observed in 34 patients; 30% (9 in 30) and 89.29% (25 in 28) of patients who had *H. pylori* negative and positive, respectively (Figure 3). In addition, the collect-



**Figure 3.** The comparison of the collecting venules pattern in *H. pylori* positive patients to *H. pylori* negative patients.

**Table 2.** The accuracy of the collecting venules pattern to predict *H. pylori* infection.

Type	Sensitivity (%)	Specificity (%)	PPV (%)	NPV (%)	Overall validity (%)
IAC	86.36	75	73.07	87.5	80
OAC	66.6	91.3	75	87.5	84.37
IAC/OAC	89.2	70	73.5	87.5	79.3

ing venules pattern at lesser curvature near incisura angularis has been shown to be sensitive for assessment *H. pylori* infection (Sens.89.2%, and NPV 87.5%) in the patient with dyspepsia when compared with the collecting venules pattern at fundus of the stomach (Sens. 25%).

The negative RAC pattern at lesser curvature near incisura angularis of the stomach provided 89.2% sensitivity, 70% specificity, 87.5% NPV, and 73.5% PPV to predict *H. pylori* infection in patients with dyspepsia. Additionally, the overall validity of using the negative RAC pattern to diagnose *H. pylori* infection was 79.3 % (Table 2).

The accuracy of *H. pylori* infection when using only the OAC pattern had 66.6% and 91.3% in sensitivity and specificity, respectively. Nevertheless the accuracy was similar to the negative RAC pattern (IAC/OAC) when using only the IAC pattern.

Finally, the interobserver agreement of the collecting venules pattern observation was good when compared between two interpreters. The concordance rate and Kappa value were 87.93% and 0.83 almost perfect agreement, respectively.

## DISCUSSION

There are many ways to diagnose *H. pylori* infection, however, many investigators still try to develop

new modalities. One of them is using the RAC to assist them for diagnosis. Initially, they used the standard EGD or the magnified endoscopy to observe the collecting venules in the stomach and reported that the accuracy is high<sup>(10)</sup>. Now there is an improved way to do by using the FICE.

This is the first study in Southeast Asia, which has a higher prevalence of *H. pylori* infection than developed countries, to use FICE to evaluate the arrangement of collecting venules.

This study found that the positive RAC pattern at the lesser curvature near incisura angularis of the stomach is highly associated with the *H. pylori* negative patients whereas the negative RAC pattern is a sensitive finding to predict the patients who had possibly been infected with *H. pylori*. This study showed that the sensitivity and specificity of the negative RAC pattern is 89.2% and 70%, respectively to predict *H. pylori* infection which is lower compared to the previous studies<sup>(10)</sup>. It probably due to many factors for instance (48%)<sup>(2)</sup>, there was no video/DVD recorded the images of the collecting venules pattern during the procedure. Because of gastric peristalsis, respiration, and patient movement, real-time image interpretation was difficult.

Although the negative RAC pattern of this study had 89.2% sensitivity and 87.5% NPV which were lower than the previous studies, these percentage were

acceptable to use a primary tool for screening *H. pylori* infection in developing countries which have high prevalence of *H. pylori* infection.

Finally, in our opinion, the virtual chromoendoscopy such as the FICE, NBI, and I-scan can use easier than the magnifying or high resolution endoscopy because this function is a part of the video processor unit that can use parallel to the conventional EGD. Additionally, its cost is lower as well.

### CONCLUSION

The abnormal arrangement of collecting venules (IAC or OAC) at lesser curvature near incisura angularis of the stomach provided the acceptable sensitivity and negative predictive value in diagnosis of *H. pylori* infection in patients with dyspepsia.

### REFERENCES

- Graham DY and Sung JJ. *Helicobacter pylori*. In: Sleisenger and Fordtran's gastrointestinal and liver disease. 8<sup>th</sup> ed. p. 1049-66.
- Atisook K, Kachinthorn U, Luengrojanakul P, *et al*. Histology of gastritis and *Helicobacter pylori* infection in Thailand: a nationwide study of 3776 cases. *Helicobacter* 2003;8:132-41.
- Yagi K, Nakamura A, Sekine A. Characteristic endoscopic and magnified endoscopic findings in the normal stomach without *Helicobacter pylori* infection. *J Gastroenterol Hepatol* 2002;17:39-45.
- Yagi K. Endoscopic features and magnified views of the corpus in the *Helicobacter pylori*-negative stomach. *Dig Endosc* 2001;13:S34-35.
- Nakagawa S, Kato M, Shimizu Y, *et al*. Relationship between histopathologic gastritis and mucosal microvascularity: observations with magnifying endoscopy. *Gastrointest Endosc* 2003;58:71-5.
- Yagi K, Honda H, Yang JM, *et al*. Magnifying endoscopy in gastritis of the corpus. *Endoscopy* 2005;37:660-6.
- Anagnostopoulos GK, Yao K, Kaye P, *et al*. High-resolution magnification endoscopy can reliably identify normal gastric mucosa, *Helicobacter pylori*-associated gastritis, and gastric atrophy. *Endoscopy* 2007;39:202-7.
- Nakayama Y, Horiuchi A, Kumagai T, *et al*. Discrimination of normal gastric mucosa from *Helicobacter pylori* gastritis using standard endoscopes and a single observation site: studies in children and young adults. *Helicobacter* 2004;9:95-9.
- Machado RS, Viriato A, Kawakami E, *et al*. The regular arrangement of collecting venules pattern evaluated by standard endoscope and the absence of antrum nodularity are highly indicative of *Helicobacter pylori* uninfected gastric mucosa. *Dig Endoscopy* 2008; 40:68-72.
- Schneider AW, Vogell H, Naumann M, *et al*. Computed virtual chromo endoscopy: usefulness for identification of histologically normal mucosa in the gastric corpus. *Gastrointest Endosc* 2008;67:AB259.