

*Ridtitid W
Komolmit P
Klaikaew N
Rerknimitr R*

CASE 1

An 85-year-old man presented with fever, jaundice and right upper quadrant pain for 2 days. He had a history of an open cholecystectomy during the last 20 years. An upper abdominal ultrasonography showed diffuse common bile duct and intrahepatic bile ducts dilatation.

Endoscopic retrograde cholangiopancreatography (ERCP) was done as shown in Figure 1.

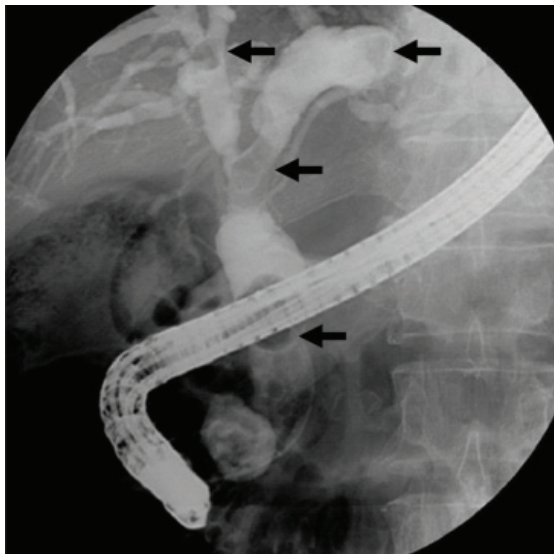


Figure 1.

Cholangiogram showed multiple round filling defects varying in sizes in common bile duct and both intrahepatic bile ducts (black arrows), the largest was 1.5 cm. in diameter.

The diagnosis is common bile duct and intrahepatic duct stones.

Mechanical lithotripsy and biliary orifice dilation with controlled radial expansion (CRE) balloon (diameter range of 15-18 mm.) were performed to extract stones as shown in Figures 2 A and B.

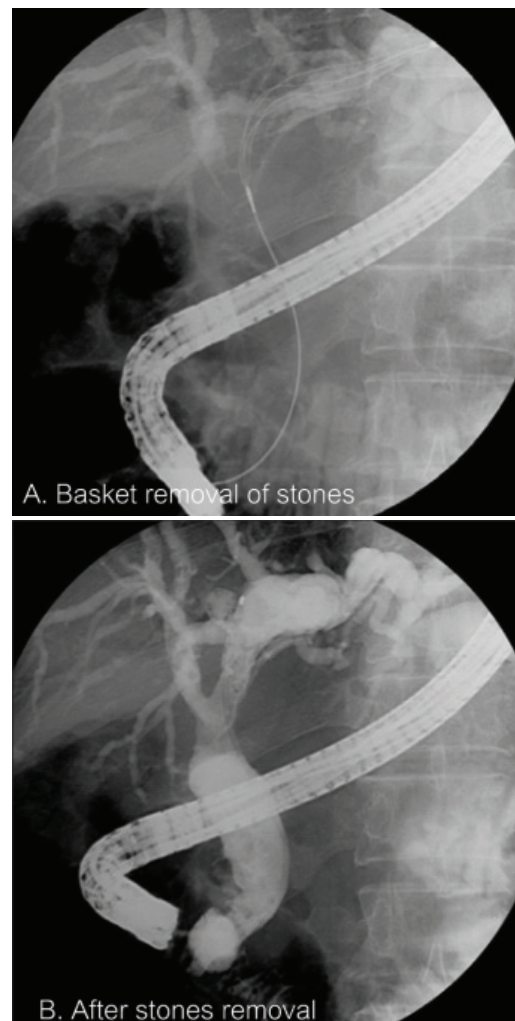


Figure 2.

Discussion

ERCP with sphincterotomy (EST) with stone extraction is a well-established therapeutic procedure for the treatment of bile duct stones. The rate of successful extraction declines with the increasing size of stone. Generally, bile duct stones up to 1.5 cm. in diameter can be extracted after EST. Majority of CBD stones (85% to 90%) can be removed with a Dormia basket or balloon catheter. Methods for managing “difficult stones” include mechanical lithotripsy, intraductal shock wave lithotripsy, extracorporeal shock wave lithotripsy, chemical dissolution, and biliary stenting⁽²⁾. Some studies have shown that papillary balloon dilation with CRE balloon after endoscopic sphincterotomy

is an effective and safe technique for retrieval of large common bile duct stones^(3,4).

REFERENCES

1. Kim HJ, Choi HS, Park JH, *et al.* Factors influencing the technical difficulty of endoscopic clearance of bile duct stones. *Gastrointest Endos* 2007;66:1154-60.
2. Binmoeller KF, Schafer TW. Endoscopic management of bile duct stones. *J Clin Gastroenterol* 2001;32:106-18.
3. Ersoz G, Tekesin O, Ozutemiz AO, *et al.* Biliary sphincterotomy plus dilation with a large balloon for bile duct stones that are difficult to extract. *Gastrointest Endos* 2003;57:156-9.
4. Maydeo A, Bhandari S. Balloon sphincteroplasty for removing difficult bile duct stones. *Endoscopy* 2007;39:958-61.

CASE 2

A 49-year-old man presented with fever and right upper quadrant pain for 2 days. He had an underlying end-stage renal disease and undergoing regular hemodialysis. Physical examination revealed mild jaundice and right upper quadrant tenderness.

Endoscopic retrograde cholangiopancreatography (ERCP) was done as shown in Figure 3.

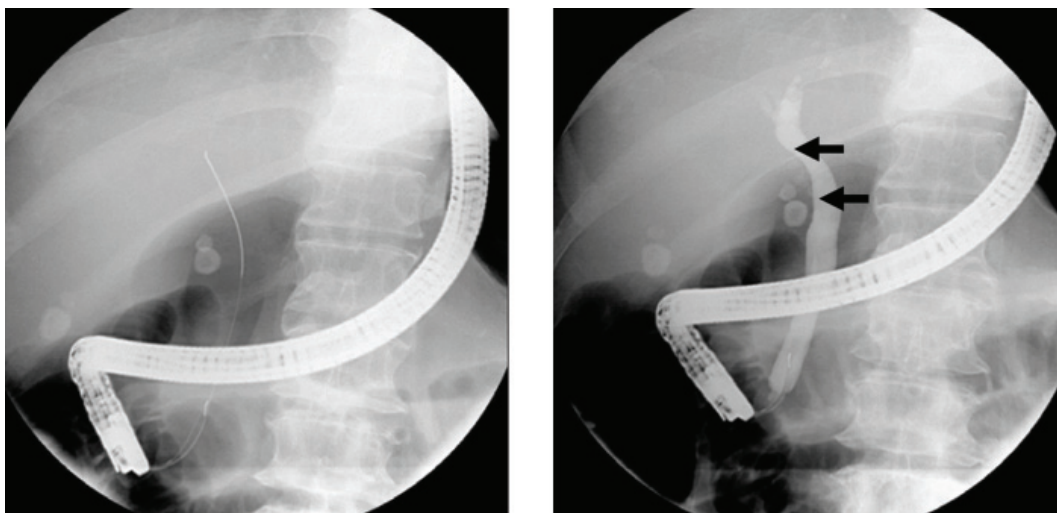


Figure 3.

Cholangiogram showed gallstones and a few stones in the cystic duct with extrinsic compression of the common hepatic duct (black arrows).

The diagnosis is acute cholecystitis with type I Mirizzi syndrome.

Standard sphincterotomy, balloon extraction, and cystic duct stent insertion was performed as shown in Figure 4. Two weeks later, cholangitis improved and open cholecystectomy was done electively.

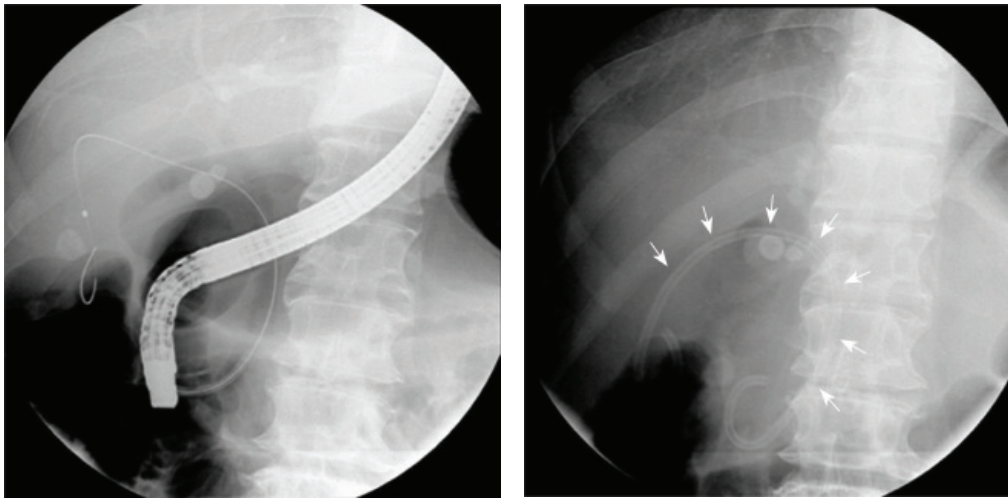


Figure 4.

Discussion

Mirizzi syndrome is a rare complication of cholelithiasis that accounts for 1% of all patients with gallstone disease. This syndrome is a form of obstructive jaundice caused by either a stone impacting gallbladder neck or the cystic duct that impinges on the common hepatic duct with or without a cholecystocholedochal fistula⁽¹⁾. Management of this syndrome is extremely varied. Recently, endoscopic therapy has been increasingly used in the evaluation and treatment of patients with Mirizzi syndrome. Endoscopic treatment is preferred in a high operative risk patient. Outcomes in several small case series suggested that endoscopic placement of a double-pigtail stent between the gallbladder and the duodenum via the cystic and

common bile ducts may prevent or treat symptoms caused by gallbladder disease^(2,3).

REFERENCES

1. Yonecti N, Kutluane U, Yilmaz M, *et al.* The incidence of Mirizzi syndrome in patients undergoing endoscopic retrograde cholangiopancreatography. *Hepatobil pancreat Dis Int* 2008; 7:520-4.
2. Conway JD, Russon MW, Shrestha R. Endoscopic stent insertion into the gallbladder for symptomatic gallbladder disease in patients with end-stage liver disease. *Gastrointest Endosc* 2005; 61:32-6.
3. Schlenker SC, Trotter JF, Shah RJ, *et al.* Endoscopic gallbladder stent placement for treatment of symptomatic cholelithiasis in patients with end-stage liver disease. *Am J Gastroenterol* 2006;101:278-83.

CASE 3

A 63-year-old man presented with painless jaundice for 5 months. Liver function test showed cholestatic pattern. Serum IgG4 level was 1670 mg/dL. CT scan of the upper abdomen revealed prominent pancreatic head with a suspicion for an ill defined mass like lesion. Endoscopic retrograde cholangiopancreatography (ERCP) was done as shown in Figure 5.

ERCP showed a long narrowing of distal common bile duct (white arrow) with upstream dilatation of common hepatic duct and bilateral intrahepatic ducts as shown in Figure 5 A.

The diagnosis is autoimmune pancreatitis (AIP)

causing distal CBD stricture.

He underwent a standard sphincterotomy and double pigtail stent was inserted as shown in Figure 5 B. Endoscopic ultrasonography (EUS) showed diffuse hypoechoic lesions at pancreatic head. Fine needle aspiration revealed negative for malignancy.

After treatment with prednisolone for 2 months, repeated ERCP with stent removal showed a significant improvement of the distal biliary stricture as shown in Figure 5 C and 5 D. The patient reported no recurrent symptoms as unremarkable laboratory findings after stopping prednisolone.

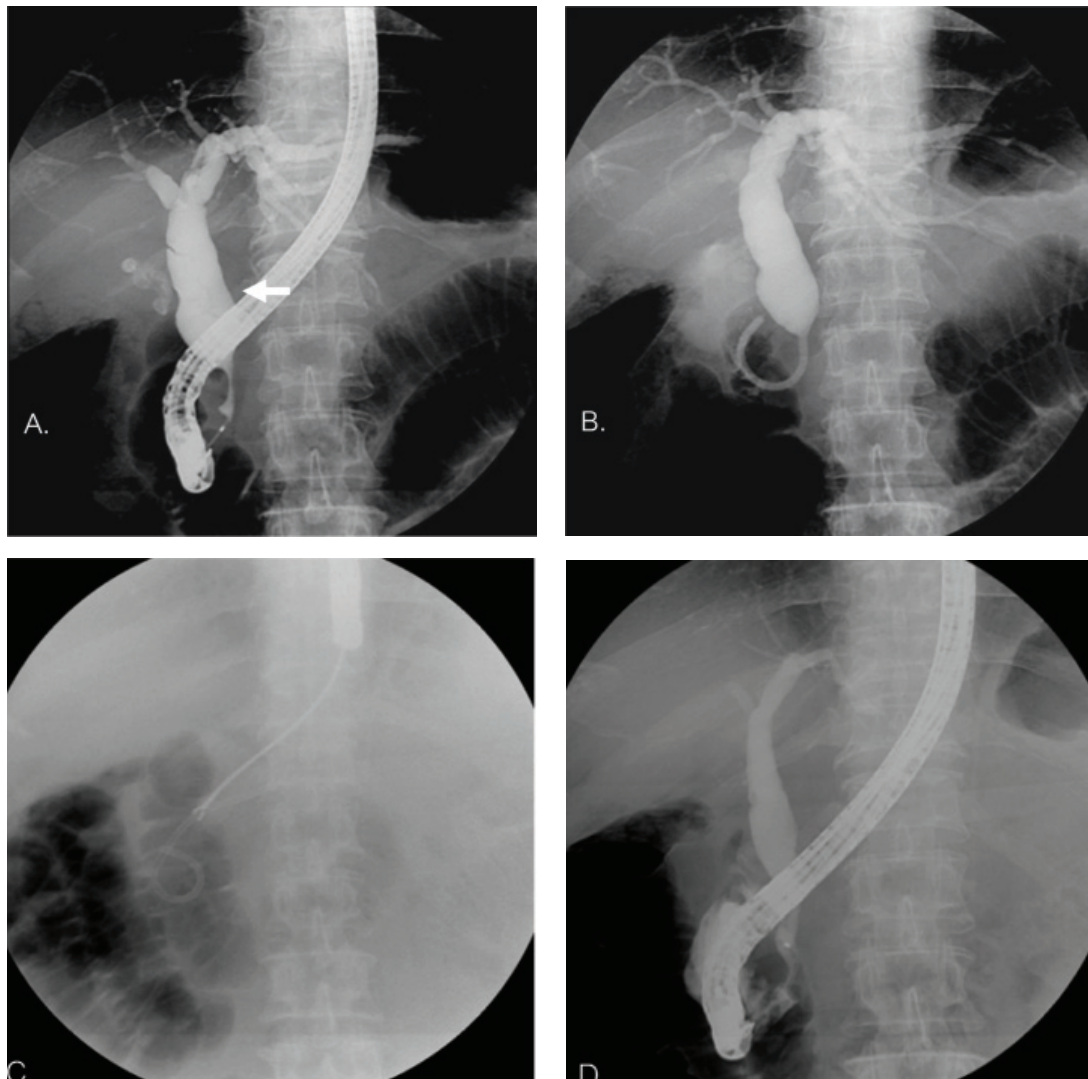


Figure 5.

Discussion

AIP is a benign fibroinflammatory form of chronic pancreatitis. The most common presentation (> 60%) is obstructive jaundice associated with biliary stricture (s) and a focal mass or diffuse enlargement of the pancreas⁽¹⁾. The major differential diagnosis is pancreatic or biliary tract cancer. Hence, many clinicians were misled for surgical resection. The extrapancreatic manifestations of AIP including biliary strictures, sclerosing cholangitis, sialadenitis, retroperitoneal fibrosis, hilar or abdominal lymphadenopathy, chronic thyroiditis, interstitial nephritis, and inflammatory bowel disease can be seen in up to 49% of patients. One antibody that can be used as a serologic marker for the diagnosis of AIP is IgG4. The treatment of choice for AIP is steroid therapy, which has been shown to improve the symptoms, reverse the inflammatory process

and resolve of the radiographic and laboratory abnormalities.

Patients should respond to steroid therapy within 2 to 4 weeks. If imaging and laboratory studies fail to show improvement, the diagnosis of AIP should be re-evaluated^(2,3).

REFERENCES

1. Okazaki I, Kawa S, Kamisawa T, *et al.* Clinical diagnostic criteria of autoimmune pancreatitis: revised proposal. *J Gastroenterol* 2006;41:626-31.
2. Yadav D, Notahara K, Smyrk TC, *et al.* Idiopathic tumefactive chronic pancreatitis: clinical profile, histology, and natural history after resection. *Clin Gastroenterol Hepatol* 2003;1:129-35.
3. Krasinskas AM, Raina A, Khalid A, *et al.* Autoimmune pancreatitis. *Gastroenterol Clin N Am* 2007;36:239-57.

Ridditid W, *et al.*

CASE 4

A 58-year-old man presented with fatigue and abnormal liver function test over the last 2 years. Liver biopsy was done and autoimmune hepatitis was suspected. Treatment with prednisolone and azathioprine

had been given for 2 months and was stopped due to frequent severe infections. Liver function test was not improved and still showed cholestatic pattern.

Endoscopic retrograde cholangiopancreatography (ERCP) was done as shown in Figure 6.

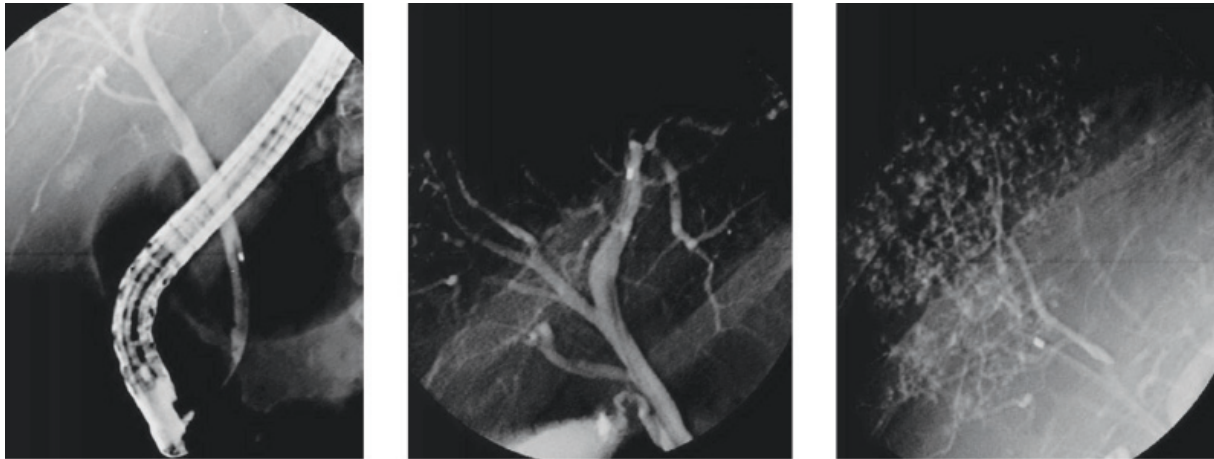


Figure 6.

Cholangiogram of the intrahepatic duct showed short focal strictures that alternated with normal ducts resulting in a “beaded” appearance of ductal structures. The remainder of extrahepatic ducts were spared.

The differential diagnosis are sclerosing cholangitis (primary VS secondary) and autoimmune pancreatitis.

Liver biopsy was done as shown in Figure 7.

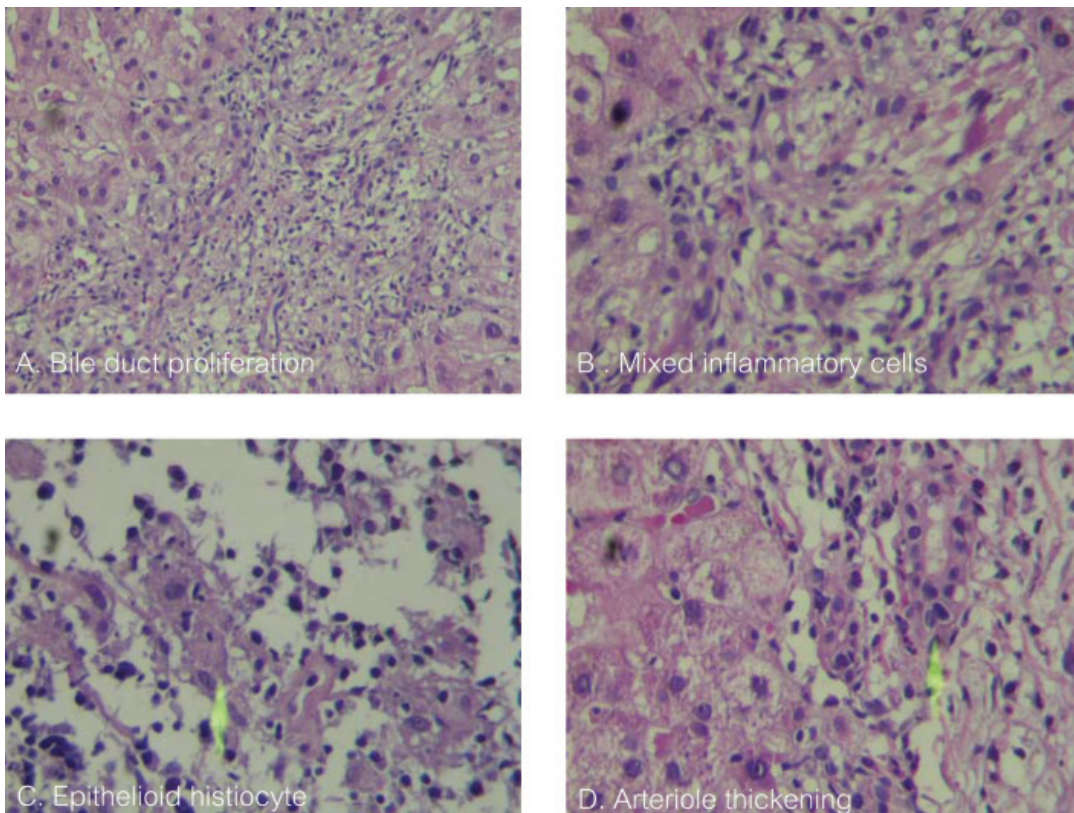


Figure 7.

Liver biopsy showed proliferative and serpiginous appearance of ducts that contains lymphocytic infiltration through the duct basement membrane in between the duct epithelial cells. Focal aggregation of epithelioid histocytes is noted together with thickening of hepatic arterioles. The most likely diagnosis is secondary sclerosing cholangitis.

Discussion

Sclerosing cholangitis is a spectrum of chronic, variably progressive cholestatic diseases of the intrahepatic and/or extrahepatic biliary system^(1,2). It is characterized by patchy inflammation, fibrosis, and structuring. The classical findings on cholangiogram are multifocal strictures, segmental dilatation, diverticulum-like outpouchings, and irregular beading of large and/or peripheral smaller bile ducts. The causes

of secondary cholangitis are obstruction (from cholelithiasis, stricture, or infection), congenital anomalies, pancreatic disorders, toxin, ischemia, and neoplasms^(1,2). Bile duct ischemia is one of the earliest events leading to biliary cast formation and ischemic-like cholangiopathy in critically ill patients⁽³⁾.

REFERENCES

1. Abdalian R, Heathcote EJ, Sclerosing cholangitis: a focus on secondary causes. *Hepatology* 2006;44:1063-74.
2. Nakazawa T, Ohara H, Sano H, *et al.* Cholangiography can discriminate sclerosing cholangitis with autoimmune pancreatitis from primary sclerosing cholangitis. *Gastrointest Endosc* 2005;60:937-44.
3. Gelbmann CM, Rummele P, Wimmer M, *et al.* Ischemic-like cholangiopathy with secondary sclerosing cholangitis in critically ill patients. *Am J Gastroenterol* 2007;102:1221-9.